Journal of Cardiovascular Computed Tomography 9 (2015) 493–513

Contents lists available at ScienceDirect

Journal of Cardiovascular Computed Tomography

journal homepage: www.JournalofCardiovascularCT.com

Guidelines

# Computed Tomography Imaging in Patients with Congenital Heart Disease, Part 2: Technical Recommendations. An Expert Consensus Document of the Society of Cardiovascular Computed Tomography (SCCT) ***Endorsed by the Society of Pediatric Radiology (SPR) and the North American Society of Cardiac Imaging (NASCI)***

B. Kelly Han [a,*], Cynthia K. Rigsby [b], Jonathon Leipsic [c], Dianna Bardo [d], Suhny Abbara [e], Brian Ghoshhajra [f], John R. Lesser [g], Subha V. Raman [h], Andrew M. Crean [i], Edward D. Nicol [j], Marilyn J. Siegel [k], Anthony Hlavacek [l]

[a] *Minneapolis Heart Institute, The Children's Heart Clinic at the Children's Hospitals and Clinics of Minnesota, Minneapolis, MN, USA*
[b] *Northwestern University Feinberg School of Medicine and Ann & Robert H Lurie Children's Hospital of Chicago, Chicago, IL, USA*
[c] *University of British Columbia, Vancouver, Canada*
[d] *Phoenix Children's Hospital, Phoenix, AZ, USA*
[e] *University of Texas Southwestern Medical Center, Dallas, TX, USA*
[f] *Massachusetts General Hospital, Boston, MA, USA*
[g] *The Minneapolis Heart Institute, Minneapolis, MN, USA*
[h] *Ohio State University, Columbus, OH, USA*
[i] *Toronto General Hospital, Toronto, Canada*
[j] *Royal Brompton Hospital, London, United Kingdom*
[k] *Washington University School of Medicine, St. Louis, MO, USA*
[l] *Medical University of South Carolina, Charleston, SC, USA*

ARTICLE INFO

*Article history:*
Received 23 June 2015
Accepted 17 July 2015
Available online 28 August 2015

## Preamble

This is the second of two complementary documents commissioned by the SCCT to provide recommendations on the use and optimal performance of cardiac computed tomography (CT) in patients of all ages with congenital heart disease (CHD). The aim of the first document was to describe the current uses of cardiac CT in CHD, review the risks and limitations of current CT technology, provide lesion specific indications for appropriately selected patients, and outline a consensus opinion on the essential skills and knowledge needed to perform cardiac CT in patients with CHD.[1] An extensive literature review is included in the part 1 document. The aim of this second document is to provide recommendations on patient preparation and technical scan acquisition for the most commonly referred CHD lesions, and to provide a brief description of radiation dose reduction techniques specific to CT in CHD.

The clinical use of cardiac CT in CHD is evolving rapidly and this document is based on the authors' experience, supported by literature when available. The population of adults with congenital heart disease is rapidly increasing as a result of improved outcomes of medical, surgical and catheter-based treatment strategies.[2–4] As patients live longer, there is a greater need for coronary imaging in addition to anatomic imaging, increased use of electrophysiology devices that are MRI unsafe, and higher prevalence of metallic implants that adversely affect MRI image quality. For these patients, CT is increasingly the preferred imaging modality when echocardiography is insufficient to answer the clinical question. This consensus document assumes competence in cardiac CT imaging, and will focus on tailoring the exam for the most commonly referred CHD lesions.

The goal of this document is to provide guidance regarding:

- Individualized patient preparation.
- Acquisition protocols for the most commonly referred CHD lesions.
- Brief overview of radiation dose reduction techniques.

* Corresponding author.
*E-mail address:* khan@chc-pa.org (B.K. Han).

http://dx.doi.org/10.1016/j.jcct.2015.07.007
1934-5925/© 2015 Society of Cardiovascular Computed Tomography. Published by Elsevier Inc. All rights reserved.

## 1. Recommendations for the use of computed tomography imaging in CHD

Patients with CHD have a large variety of anatomic variations. Most patients will come to the CT scanner with a known cardiac diagnosis based on prior imaging studies.[5–8] The cardiac CT scan is usually ordered to answer a specific clinical question to help with the medical or interventional management of the patient. Each cardiac CT exam must be tailored to the patient to minimize risk and maximize diagnostic yield. Performing cardiac CT for CHD requires an in depth knowledge of the patient history, prior intervention(s), common hemodynamic sequelae, and the clinical question(s) to be answered by the study. The scan range, acquisition parameters, desired image quality, and the degree of radiation dose reduction will vary greatly depending on the patient and clinical indication. For instance, optimal imaging of the coronary arteries requires a breath hold, slow and regular heart rate, and the highest temporal and spatial resolution available on the scanner platform. For many indications in CHD, this level of image quality, spatial resolution, and/or temporal resolution is not required and aggressive radiation dose reduction techniques may be used.[9–12] The principles below describe a general approach to the performance of cardiac CT in patients with CHD. The imaging physician needs to be actively involved in directing patient preparation and image acquisition for each cardiac CT performed for CHD. The interpretation and reporting of scans in patients with CHD is time-consuming and requires dedicated time and effort. Expertise in CHD CT imaging combines the skill sets and knowledge base of both cardiology and radiology.

This Writing Group strongly advocates a collaborative approach to CHD CT imaging that includes pediatric and adult cardiologists, cardiac imagers and surgeons. Several questions should be asked prior to selection of CT as the imaging test of choice in CHD:

1. Does the study indication justify the risks of CT (radiation and contrast exposure, anesthesia and/or medication for heart rate control when needed)?
2. Does cardiac CT have the ability to best answer the clinical questions at the least risk to the patient when compared to alternate diagnostic modalities locally available?
3. Will the results provide the information necessary to impact clinical management of the patient?

The optimal CT imaging environment and core knowledge considered essential for high quality cardiac CTA in CHD is present in Table 1A & 1B.[1] Situations where CT may be appropriate in patients with CHD is outlined in Table 1C.[1]

### 1.1. Recommendations for CT facility and support staff personnel

Non-invasive CT imaging of the coronary arteries (CCTA), complex CHD and valvular function requires isotropic data sets with high temporal and spatial resolution. Newer scanner technologies allow for imaging of the heart and coronary arteries in one or several heart beats, with significantly improved diagnostic performance over older CT technology. The major advantages of newer technology scanners for CCTA are a reduction in nondiagnostic scans or non-evaluable coronary segments and a substantial

**Table 1A**
Optimal imaging environment for CHD imaging with cardiovascular CT.

| |
|---|
| Alternate cardiac imaging modalities are available so that the test with the least risk can be performed for a specific clinical indication |
| Close collaboration & communication is present among surgeons, clinical cardiologists and imagers |
| All patient clinical information is accessible to allow understanding of the clinical indication and potential management options for the patient |
| Scan protocols can be designed and adjusted to extract maximum clinical information at minimum procedural risk |
| Technologists are experienced in cardiac CT and comfortable with varied cardiac scan modes |
| Easy access to pacemaker programming to allow rate and mode adjustment when needed |
| Nursing support to facilitate administration of medication for heart rate control when necessary in patients with and without permanent pacemakers, and to provide appropriate monitoring for any side effects |
| Access to all forms of prior imaging reports (echocardiography, angiography, nuclear, CMR) so that a targeted evaluation may be performed for an individual patient |
| Post processing workstations capable of handling large multiphase data sets for advanced reconstructions |
| High-speed network to transfer large volume data sets from scanner to workstation |
| Immediate availability of resuscitation equipment and resuscitation team appropriate for the size and age of the patient |

**Table 1B**
Relevant knowledge for the performance of cardiovascular CT in CHD patients.

| |
|---|
| **Cardiac/CHD specific knowledge required** |
| Anatomy & physiology of CHD – natural and repaired |
| Surgical procedures used to palliate or repair CHD |
| Catheter interventions used to palliate or repair CHD |
| Material composition of the surgical materials or catheter devices used and the artifact produced with different imaging modalities (MRI and CT) |
| Common residual hemodynamic lesions following initial CHD repair |
| Indications for re-intervention (ACC/AHA/ESC/CCS guidelines) |
| Normal coronary anatomy |
| Congenital coronary anomalies and the indications for and methods of repair |
| Basic EKG knowledge and arrhythmia recognition (and impact on imaging strategy) |
| Pediatric and adult doses for heart rate lowering medications and sublingual nitroglycerin, and contraindications to these medications |
| **CT technique-specific knowledge required** |
| Training and experience in congenital cardiac CT (there are no current educational standards for CHD CT) |
| Scanning principles and scan modes |
| Contrast injection protocols adjusted for both patient size and cardiac pathology |
| Prophylaxis against and treatment of minor and major contrast reactions |
| Radiation physics and basics of radiation dose measurement |
| Radiation dose reduction strategies and individualized scan planning |
| Familiarity and competence with post-processing methods and software |
| Familiarity with standards for quantification and reporting in CHD |

**Table 1C**
Situations in which cardiovascular CT may be considered in CHD.

| |
|---|
| Presence of CMR incompatible implant or foreign body (retained pacing leads, non-MR compatible pacemaker/defibrillator, neurostimulator) |
| Poor CMR image quality (known or expected) due to metallic artifact |
| Unable to fit in MRI scanner due to obesity; or severe claustrophobia |
| Neonate or young patient requiring evaluation of complex anatomy, particularly if considered higher risk for adverse event with anesthesia required for CMR, and the CT scan can be performed with no or limited sedation |
| Critically ill patient of any age that may not tolerate breath holding or length of CMR scan |
| Evaluation of ventricular assist device or ECMO cannula positioning |
| Patient requiring CT for evaluation of extra-cardiac anatomy in addition to CHD (e.g. lung parenchyma, airway, skeletal abnormality) |
| Pre-operative patients with prior sternotomy considered high risk for vascular injury with sternal reentry due to an anterior coronary artery, conduit, or sternal adhesions |
| Evaluation of prosthetic valve function or structural integrity (calcification, stenosis, coaptation defect, leaflet immobility, paravalvular leak) |
| Evaluation of calcification within vessels and surgical conduits prior to catheter-based intervention (e.g. balloon angioplasty, transcatheter valve replacement, stent placement) |
| Coronary artery imaging in CHD: |
| • Patient needing detailed pre-operative coronary artery evaluation in addition to assessment of complex anatomy |
| • Patient with symptoms and signs suggestive of atherosclerotic coronary artery disease and a history of CHD, prior coronary intervention, or high risk Kawasaki disease |
| • Young symptomatic patients with known or suspected coronary anomaly, particularly if CMR is unlikely to provide complete assessment or more likely to require anesthesia |
| • Delineation of coronary anatomy prior to percutaneous pulmonary valve implantation |
| • Evaluation of coronary artery after any surgery requiring reimplantation |

improvement in per-patient specificity and positive predictive value. There is also decreased systolic motion artifact of the proximal great vessels on newer generation technology that captures an image in a fraction of, or specific portion of, the cardiac cycle.

For many non-coronary indications, older generation scanners are adequate for image acquisition. Non-invasive CT imaging of mediastinal vessels can be performed using 16 detector technology, although image quality will be improved using scanners with 64 detectors or greater. Older generation scanners acquire data during a larger portion of the cardiac cycle, or during both systole and diastole in a non ECG gated scan. In this case, systolic motion artifact may obscure the proximal ascending aorta in particular and can be misinterpreted as a Type A aortic dissection. The need for sedation or anesthesia may be increased in older generation MDCT scanners that acquire data over several seconds since there is increased potential for artifact from both breathing and patient motion.

Newer generation MDCT scanners also offer the advantage of submillimeter isotropic data sets, which improves image quality even without ECG gating. Important information about conduits, coronary arteries, baffles, thoracic arterial and venous vasculature anatomy can be assessed. The higher spatial and temporal resolution combined with rapid image acquisition will improve image quality based on both technical and patient factors in young patients.

CT Technologists performing cardiac CT in CHD should have expertise in cardiac CT, including knowledge of ECG gating techniques, contrast injection and image acquisition protocols specific to CHD. Technologists must also have expertise in patient and indication specific radiation dose reduction techniques.

## 2. Pre-procedure guidelines and patient preparation recommendations

### 2.1. Anesthesia and sedation requirements

For detailed coronary imaging in patients of all ages, breath holding is usually required during image acquisition to eliminate respiratory motion. For other anatomic imaging, the need for a breath hold is dependent on the acquisition time of the scan, the size of the structure to be visualized, and the image quality required. For newer generation scanners the time of image acquisition is less than a second or a single heartbeat. Techniques such as half-scan reconstruction, prospectively ECG triggered high pitch scan mode or volumetric target mode reduce both respiratory and cardiac motion. With this technology cardiac anatomy and proximal coronary course can be visualized without a breath hold.[13–16] For older generation scanners with images acquired over several seconds or multiple heart beats, breath holding may be required to reduce motion artifact, particularly when trying to image small cardiac structures.

#### 2.1.1. Recommendations for anesthesia and sedation

- Anatomy only (non-coronary):
  - Most infants can be swaddled and imaged without sedation. Use of oral 25% dextrose solution and a pacifier may help calm a baby when upset.
  - Patients 6 months to 3 years of age often require sedation to lie still in the scanner, but can usually be imaged free-breathing. Video distraction or immobilization devices are available for this age patient.
  - Most patients 4 years of age or older who are developmentally appropriate for age can cooperate with holding still in the scanner without sedation. The presence of a parent in the room or child-life services may be helpful.
  - Most patients 7 years of age or older who are developmentally appropriate for age can cooperate with a breath hold.
  - Use of scanners with volumetric acquisition or ultra-high pitch scanning modes should decrease the need for sedation in children of all ages due to the short acquisition time.
- Coronary artery or functional imaging:
  - <u>When only proximal coronary artery definition is requested to assist in surgical planning</u>: There is relatively little systolic motion of the proximal coronary arteries, even at higher heart rates. As a result, diagnostic imaging of the proximal coronary arteries may be possible without sedation or breath hold if using prospectively ECG triggered high pitch or volumetric target scan mode.[11,17]
  - For these patients, the sedation requirements are similar to non-coronary applications above.
  - <u>When detailed coronary artery imaging or ventricular function is requested (including detailed ostial anatomy)</u>: Most scan sequences used for detailed coronary artery imaging at fast heart rates and functional imaging acquire data over several heart beats. Patients younger than 5–6 years of age

will need general anesthesia for cooperation with breath holding when high resolution or detailed coronary anatomy or functional imaging is needed (generally one breath hold). For those able to cooperate, practicing the breath hold with the patient prior to imaging is often helpful to both assure cooperation and to assess the respiratory variability of the heart rate.

#### 2.1.2. IV type and gauge

A peripheral IV line is most commonly used for contrast injection for congenital cardiac CT scans, and is the preferred form of access for power injection with automated devices. PICC lines, central lines, and indwelling venous catheters have all been described for safe injection as well, although hand injection is commonly used with these access types.

Umbilical catheters can be safely used but may result in suboptimal contrast enhancement due to reflux of contrast into the liver. Due to the high incidence of intra-cardiac shunting in patients with complex congenital heart disease, particular care to avoid any air bubbles in the injection is important, as it may result in a systemic arterial embolus. In general, the largest gauge IV cannula feasible for the patient body size is optimal for contrast injection. Most practitioners use a direct connection between the power injector and the hub of the peripheral IV. The IV gauge should be determined based on the maximum anticipated flow rate of contrast injection. Warming the contrast will decrease viscosity and allows for safer injection if the rate is at the higher limits of the catheter.[18] Both the IV gauge and the IV site should be considered when determining flow rates. Slower rates may be preferred for small venous structures such as the hand or foot in a baby or small child. The following are general guidelines for flow rates and pounds per square inch (psi) based on IV gauge:

24 gauge: 0.5–1.5 ml/s, maximum 50–100 psi
22 gauge: 2–3.5 ml/s, maximum 100–300 psi
20 gauge: 3–5 ml/s, maximum 300 psi
18 gauge: 4–6.5 ml/s, maximum 300 psi

#### 2.1.3. IV location

The location for contrast injection should be determined in advance so that IV placement is appropriate for the study indication. The optimal location of a peripheral IV may vary by cardiac lesion. An upper extremity antecubital IV cannula is most commonly used and is generally preferred for most indications. Injections performed via the right upper extremity, rather than the left, may help minimize streak artifact in the arch vessels due to residual high density contrast in the left brachiocephalic vein. Injection via a lower extremity vein may be considered in neonates and infants to avoid residual high-density contrast in the SVC, particularly when pathology or anomalous drainage of the right pulmonary veins is suspected. For patients with anomalous systemic venous drainage such as an interrupted IVC, bilateral SVC, or suspected central venous occlusion, IV placement may need to be in a certain location to optimize opacification of the structure of interest. For example, if an interrupted IVC is suspected, contrast injection in the lower extremity will guarantee that the structure is opacified, rather than relying on venous recirculation. If a venous thrombotic occlusion is suspected, injection may result in cardiac opacification via collateral vessels, making timing of image acquisition difficult. Additionally, contrast swirling with unopacified blood during image acquisition can be difficult to differentiate from thrombus or venous occlusion (e.g. imaging a Fontan circuit). Beam hardening artifact may interfere with the assessment of a vessel or surrounding structures. When these possibilities are present, it may be best to visualize the structure during venous recirculation. At the low contrast injection rates used in the smallest patients, contrast arrival in the heart will vary based on IV location and transit time. This needs to be accounted for in scan monitoring and timing of image acquisition to avoid imaging too early or late for the contrast bolus.

#### 2.1.4. Use of power injectors

Power injectors can be safely used in pediatric patients with any IV $\geq$ 24 gauge, depending on patient size.[19] Standard power injection is performed with the power injector set at 50–300 psi. The rate of injection and psi should be adjusted for the IV gauge. A 22 gauge IV or larger is preferred, but safe injection through a 24 gauge has been reported for neonates at low flow rates of 0.5–1.5 ml/s.[19] When using a power injector through a small gauge IV, a saline test injection with careful observation of the injection site and psi should be used prior to contrast injection to evaluate the integrity of both the injector connection to the IV and the IV itself. The psi achieved for a contrast injection will be higher than that for an equivalent amount of saline through the same IV. Power injection through central lines not specifically designed for power injection is not recommended by the FDA or central line manufacturers.

Power injection through central lines can be safely performed if pressure-limited injection is employed.[20] The package insert regarding maximum allowed psi should be verified for each central line prior to use. If this information is not available, a hand injection should be considered. For pressure-limited injection, both the injection rate and maximum psi allowed for the catheter are set, and the injector will inject contrast at the allowed pressure to avoid catheter rupture. For the same set psi, the contrast injection rate will vary significantly based on catheter length and size, and may not allow for adequate injection rates except in neonates and young children.[20,21] A pressure-limited injection to a maximum of 25 psi has been used safely in small central catheters with acceptable opacification in patients less than 30 kg. Many power injectors have a lower pressure limit of 50 psi, which is higher than recommended for most small gauge indwelling pediatric catheters.[20] The small bore of some catheters (3 Fr or less) may not allow for pressure limited injection. If hospital policy or clinical judgment prohibits power injection through 24g IV catheters or a central line, hand injection of contrast can be used.

#### 2.1.5. Contrast volume and injection protocols

The total contrast volume used for pediatric CT angiography is typically 1–2 ml/kg until standard adult contrast volumes are achieved. The combined volume load of the contrast and saline flush is 2–3 ml/kg and is usually tolerated without hemodynamic consequence. The minimum time between scan initiation and image acquisition can be as long as 4 s with certain scan protocols. Mixing contrast and saline to lengthen the injection time increases the chance of optimal enhancement at the time of image acquisition for scans with very short image acquisition times, longer scan delays, or variable contrast transit times. A longer contrast injection may result in high density contrast in the venous inflow when the data is acquired, creating streak artifact that affects adjacent structures. If streak artifact is likely to affect the diagnostic quality of a scan, later image acquisition, a tighter contrast bolus with a saline flush, or an additional scan during venous recirculation may be considered if systemic venous anatomy is needed. The following are examples of common injection protocols.

A Biphasic/dual phase injection protocol (contrast at a constant rate followed by a saline flush) is typically used to for pulmonary or systemic arterial angiography, with image acquisition timed to opacification of the vessel of interest. For patients with intra-cardiac mixing, a longer and slower contrast injection with image acquisition at the end of injection often allows venous and arterial opacification on the same scan without a separate initial bolus. This can be helpful in patients such as neonates with intra-cardiac mixing or a suspected combination of arterial and venous anomalies. An example is given for a normal sized adult, rates are adjusted to patient size (Table 2).

**Table 2**
Example biphasic/dual phase injection protocol (contrast + saline).

| | Injection rate (ml/s) | Volume (ml) | Time of injection (s) |
|---|---|---|---|
| Contrast | 6 ml/s | 100 ml | 17 s |
| Saline | 4 ml/s | 50 ml | 12.5 s |

A biventricular injection protocol (also called a triphasic procotol: two phase contrast injection followed by a saline flush) is most commonly used for simultaneous pulmonary and aortic angiography. This method is useful in patients with tetralogy of Fallot or after the arterial switch or Ross operation where both the right and left heart structures need evaluation. One method of achieving biventricular opacification is to give half the contrast at the usual arterial rate for patient size and IV, and the remainder at a slower rate, followed by a saline flush. Another option is to keep the injection rate constant and program a contrast:saline mix (e.g. 30:70 to 50:50% mix) for the second phase of the contrast bolus. Either method will result in opacification of both the right and left heart structures during image acquisition. An example is given for a normal sized adult, rates are adjusted to patient size (Table 3).

**Table 3**
Example triphasic injection protocol (biventricular opacification protocol: two phase contrast + saline).

| | Injection rate (ml/s) | Volume (ml) | Time of injection (s) |
|---|---|---|---|
| Contrast | 6 ml/s | 80 ml | 13 s |
| Contrast | 3.5 ml/s | 40 ml | 11 s |
| Saline | 3.5 ml/s | 50 ml | 14 s |

A venous two-phase injection protocol can be used when venous and arterial anatomy are both required, such as single ventricle physiology. With this method, a percentage of the contrast is given (30–50%) and followed by a 30–60 s pause. The second phase of contrast is then given as a dual phase injection as describe above (contrast at a constant rate followed by a saline flush). The Hounsfield unit (HU) trigger in the region of interest (ROI) on an automatically triggered scan should be adjusted slightly higher if this method is used to account for the venous contrast injection, or a manual scan trigger can be used from the monitoring sequence. Contrast volume and injection rates are always tailored to patient size and cardiac anatomy. In particular, the second phase contrast injection should be tailored to optimal opacification of the primary anatomy of interest. The monitoring sequence and scan acquisition should be timed to the second phase contrast injection. An example is given for a normal sized adult with single ventricle physiology (Table 4).

**Table 4**
Example venous two phase injection protocol (two phase contrast injection with a pause + saline).

| | Rate of injection (ml/s) | Volume (ml) | Length of injection (s) |
|---|---|---|---|
| Contrast | 3 ml/s | 60 ml | 20 s |
| Pause: 30–60 s | | | |
| Contrast | 5 ml/s | 70 ml | 14 s |
| Saline | 4 ml/s | 50 ml | 12 s |

### 2.2. Patient preparation

#### 2.2.1. Renal function measurement

In the first days of life, serum creatinine measurements often reflect maternal values, and are of limited value. In older infants and children without a history of kidney disease, pre-scanning measurement of renal function is usually not indicated. Patients with known or suspected renal disease should have serum creatinine drawn and e-GFR calculated prior to imaging, and have the smallest amount of contrast used that will yield a diagnostic image. Center specific guidelines should be followed when available. It is standard practice to provide hydration before and after the CT scan in patients with borderline kidney function, but its benefit in children has not been proven; and the volume status of all patients needs to be considered.

#### 2.2.2. Pregnancy testing

Most pediatric radiology centers routinely test for pregnancy testing in post-menarchal females prior to CT imaging. Each patient's relevant medical history should be taken into consideration, and institutional guidelines should be followed.

#### 2.2.3. Guidelines related to pre-scan fasting

Although most adult centers recommend no oral intake for several hours prior to CT imaging, many pediatric centers allow feeding just prior to image acquisition in infants. Institutional guidelines should be followed regarding oral intake prior to CT scanning. Unnecessarily prolonged pre-scan fasting can make IV placement difficult in small children, and certain patients with CHD (e.g. patients with a BT shunt) can become unstable with dehydration. Some patients may benefit from IV hydration prior to CT scanning.

#### 2.2.4. Pre-procedure medications

Susceptibility to motion artifact relates to the interaction between the heart rate and rhythm regularity at the time of the scan, along with the temporal resolution of the CT scanner. The need to limit motion increases when smaller sized structures in close proximity to the heart are the areas of interest. Coronary arteries are most susceptible to motion artifacts, and the use of a pre-procedural beta blocker to slow heart rate is useful to improve image quality.[22,23] Heart valves are also highly susceptible to motion, and image quality improves with heart rate control. Using a 64 detector CT scanner, artifacts are much less frequent with a heart rate less than 60 bpm compared to greater than 70 bpm.[24] Newer generation scanners with improved temporal resolution allow artifact free imaging at higher heart rates, but image quality remains heart-rate dependent.

Slower heart rates allow for more efficient use of radiation reduction algorithms with cardiac gating, and have been shown to decrease radiation dose.[25] The use of both oral and intravenous pre-scan beta blockers has been shown to be safe in adults[24,26] and in a pediatric population with simple to complex congenital heart disease.[27,28] However, safe use requires careful and appropriate patient screening for contraindications, including those patients who

are hemodynamically unstable with a compensatory sinus tachycardia. In addition, those with severe pulmonary hypertension and right heart dysfunction or severe aortic stenosis may not tolerate large beta blocker doses. Typically, patients with compensated heart failure can tolerate beta blocker protocols without complications.[22,29] Sublingual nitroglycerin has been shown to increase coronary volumes and lumen diameters on coronary CT angiography.[30] Its use is recommended in all adult patients undergoing coronary CT angiography unless they have recently taken a phosphodiesterase type 5 inhibitor. Both a beta blocker protocol[22] and nitroglycerin[30] may be considered prior to imaging coronary arteries in the setting of congenital heart disease if high resolution imaging is needed. Appropriate nursing and physician presence is recommended to ensure appropriate patient screening, medication dosing and to manage unexpected complications. Extra-cardiac structures including the pulmonary arteries, pulmonary veins, and the thoracic aorta distal to and including the aortic arch are minimally affected by cardiac motion and do not need beta blockade.

#### 2.2.5. Pre-scan preparations with cardiac devices

Many patients who require a cardiac CT angiogram to assess congenital heart disease have an indwelling permanent pacemaker and/or defibrillator. Intermittent ventricular pacing may be present and results in interspersed paced and intrinsically conducted beats, causing highly variable ventricular activation and contraction patterns.[31] Prior to a gated cardiac scan, the pacemaker device must be interrogated to identify the underlying rate and rhythm. Utilizing this information, one can determine whether beta blockade, pacemaker rate adjustment, or both is necessary. The goal is to image the patient during either the normal or paced rhythm, but not with a combination of both. The activity mode on the pacemaker should be turned off in order to avoid an inadvertent increase in heart rate related to pacemaker generator motion or increased breathing. This is especially important for the assessment of ventricular function. Contrary to early preliminary reports, CT scans do not negatively affect cardiac rhythm devices.[32] If the scan indication for a patient is to evaluate cardiac anatomy prior to biventricular pacemaker placement, coronary venous anatomy may be desired, and the scan timing should be adjusted to allow coronary venous opacification on the arterial scan. This can be accomplished by acquiring the image several seconds later than usual, and either slowing the contrast injection or giving an increased contrast load so that the arterial phase of the scan is not compromised.

#### 2.2.6. Breath holding instruction

CT imaging with suspended respiration is usually required for the highest quality images, but respiratory motion artifact generally does not significantly impact image quality with certain scan sequences on the newest volumetric or highest pitch scanners.[33] If the patient is cooperative, breath-holding instructions should be discussed prior to the scan so that the patient is aware of what to expect during the study. For most pediatric patients, practicing the breath hold several times in the scanner helps alleviate anxiety, improves compliance during scanning and the reliability of the breath hold. Suspended respiration may be performed during end-inspiration or end-expiration, whichever is shown to be more consistent for the individual patient. End inspiration is best if concomitant assessment of lung parenchyma is indicated. For those who cannot cooperate for breath holding, quiet breathing is preferred. If a patient is undergoing the CT examination under general anesthesia, suspended respiration should be used to minimize respiratory motion artifact. However, in some critically ill patients requiring high PEEP ventilator settings, breath holding should be minimized as much as possible.

#### 2.2.7. Patient positioning

All patients should be positioned at the scanner isocenter with the patient in the middle of the CT gantry. Scanning a patient without centering can lead to decreased image quality with increased image noise, and increased radiation dose.[34] Although neonates and infants <6 months can be swaddled with arms at their side or above their head for image acquisition, positioning the arms above their head is preferable; and patients >6 months of age should always be positioned with their arms above their head when possible. Keeping the arms down can create artifact when using low kV scanning and can cause the automated exposure control (if used) to increase the tube current to account for the arms.[35] If an antecubital IV is in place, efforts should be made to prevent elbow flexion with contrast injection. This can be achieved with an arm board, or with tight swaddling. If an infant or small child is scanned without sedation, a strap across the patient on the CT table will prevent movement between localizer images and the main acquisition.

## 3. Recommendations for the performance of cardiac CT in CHD

### 3.1. Scan acquisition methods (scan trigger)

#### 3.1.1. Timing bolus

A pre-scan timing bolus can be used when there is abnormal systemic or pulmonary venous return, intra-cardiac shunting, or significant ventricular dysfunction that makes optimal scan acquisition difficult to predict. This method uses some of the total contrast available for the angiogram and results in additional radiation exposure, and so is rarely used in pediatric patients. When this technique is used, the tube power and current should be decreased to reduce radiation exposure from monitoring.

#### 3.1.2. Automatic bolus tracking

Automatic triggering of the scan when the contrast reaches a pre-defined Hounsfield unit (HU) in a region of interest (ROI) placed in the structure of interest is reliable for pulmonary and arterial angiography when systemic and pulmonary venous return is normal and there is minimal or no intra-cardiac shunting. This method does not require additional contrast. The baseline HU trigger should be increased for 70 and 80 kV scanning, as the higher contrast attenuation may result in early triggering of the scan if the standard trigger is used (for example a HU trigger of 180 or 200 can be used for 70 kV scanning). As with a timing bolus, the tube power and current can be decreased to reduce radiation exposure during the monitoring sequence. Monitoring is usually set to begin mid-way to near the end of the contrast injection. The time between reaching the HU trigger and the initiation of scan acquisition is usually set to acquire the image at the end of contrast injection or during the saline flush and will vary by indication.

#### 3.1.3. Manual bolus tracking

In patients with highly complex anatomy or systemic venous abnormalities where contrast timing is difficult to predict, bolus tracking can be used to manually trigger the scan after visualization of contrast in the area of interest on the monitoring sequence. This method is similar to the automated bolus tracking, but the ROI is placed outside of the body, with the scan initiated manually from structures identified visually on the monitoring sequence. The monitoring sequence can be placed mid heart rather than in the area of the great arteries to simplify visualization with great arterial abnormalities. Image acquisition must be triggered prior to optimal opacification to account for

the scan delay, which can be as long as 4 s in the highest pitch scan mode. With experience, this can be a reliable method of scan acquisition. The monitoring sequence is usually set to begin approximately halfway through contrast injection. The tube power and current can be decreased to reduce radiation exposure from the monitoring sequence with this approach as well. This approach may be the most reliable in patients with known venous occlusions and venous collateral vessels that will not fill in the normal time frame. If high suspicion for venous obstruction, consider lengthening the number of seconds that the machine will monitor prior to initiating image acquisition so that the monitoring extends long enough to detect the contrast from wherever it fills.

#### 3.1.4. Fixed time from injection

Some authors advocate image acquisition at a preset time from the start of contrast injection in neonates and infants with higher heart rates, where the cardiovascular structures in the chest are generally opacified by the time that the contrast bolus is completed. Diluting the contrast with saline (1:1 or 2:1 ratio of contrast:saline) can lengthen the bolus to provide additional room for error. The scan should be timed to initiate once the contrast has been injected, taking into account the minimum scan delay for the scanner. This method is imprecise due to the variability of contrast transit from different injection sites, contrast injection rate, collaterals, cardiac shunting, etc. Use of this method may lead to a non-diagnostic scan in the setting of IV malfunction, unsuspected venous occlusion or systemic venous abnormality. Contrast timing can be particularly difficult to predict in children or patients with single ventricle anatomy, valvular regurgitation or ventricular dysfunction and so this technique should be avoided in these patients as well.

### 3.2. Scan sequences

The sequence utilized is highly dependent on the clinical indication. A detailed description of cardiac and thoracic scan sequences is beyond the scope of this document and is well described in the literature.[36] In general, patients requiring evaluation of structures prone to cardiac motion artifact (intracardiac anatomy, coronary arteries, and the aortic root) and those requiring functional assessment should be scanned using a sequence that is ECG-gated or triggered. Most other patients can be scanned with a non-gated sequence, although image quality is often inferior to those obtained with ECG-gated sequences.[37] If the highest pitch or volumetric scan modes are used without ECG triggering, there is little motion artifact due to the rapid image acquisition.[9,38] If available, these sequences can be used on all patients that do not require high resolution coronary artery evaluation.

Scans requiring ECG-gating may be performed using a retrospectively-gated helical sequence, prospectively-triggered axial sequence, or a prospectively triggered high pitch helical or target scan mode sequence. Retrospectively-gated sequences are the most robust for imaging coronary artery anatomy, but result in the highest radiation exposure. The acquisition window is automatically widened if arrhythmia is noted on the ECG tracing during the scan or pre-scan monitoring. Therefore, on scanners with other ECG-gated sequences available, retrospective ECG triggered scan modes should be limited to patients with significant arrhythmias or elevated heart rates. Prospectively-triggered sequential acquisition, or "step-and-shoot" acquisition, offers the benefit of a significant decrease in radiation exposure.[39] While this scan mode was initially limited to patients with heart rates <70 bpm, it has been shown to generate diagnostic coronary imaging in pediatric patients with higher heart rates.[40,41] Prospectively ECG triggered high pitch helical sequences and volumetric target scan mode result in the lowest radiation dose due to the narrow acquisition window. These scan sequences allow for an ECG-triggered scan at radiation doses that are similar to non-gated scans due to the narrow acquisition window. Detailed and high resolution coronary evaluation with the narrowest acquisition window techniques will be limited to those with lower heart rates, however.[41,42]

### 3.3. Scan acquisition protocols

The recommendations outlined below assume that the user is highly competent to perform CT in pediatric or adult patients with normal cardiac anatomy, is familiar with standard injection protocols for systemic or pulmonary arterial and venous imaging with normal cardiac physiology, and is familiar with the scan acquisition sequences. The recommendations below are for modifications of the usual cardiac CT protocols for specific CHD lesions.

#### 3.3.1. By lesion/area of interest

*3.3.1.1. Thoracic arterial abnormalities.* Patients with simple pulmonary or aortic abnormalities should be scanned with the contrast bolus timed to the area of interest. A relatively tight contrast bolus can be used per standard protocols. If there are abnormalities of both pulmonary and systemic arterial anatomy, a longer bolus allowing simultaneous opacification of both should be used. If contrast is still entering the right atrium and ventricle at the time of image acquisition, the right coronary artery can be difficult to visualize due to scatter from the high density contrast. If intracardiac mixing is present, optimal opacification may be difficult to predict as it will depend on the amount of shunting and differences in pulmonary and systemic vascular resistance. Using a longer injection or a later image acquisition will increase the change of optimal opacification for both the pulmonary and systemic circulation in these cases (Table 5).

**Table 5**
Scan modifications for thoracic arterial vasculature abnormalities.

| Patient preparation | Standard preparation |
|---|---|
| Contrast/Acquisition timing | Timed to AO or PA<br>• Longer injection for both AO and PA<br>• For ductal or shunt dependent PBF – time to aorta<br>• For ductal dependent systemic BF – time to AO or PA (both will fill near simultaneously) |
| Scan range | thoracic inlet to diaphragm<br>• Include upper abdomen if aortopulmonary collaterals or sequestration suspected (MAPCA in TOF, sequestration in Scimitar syndrome) |
| Scan sequence | Use high pitch or volumetric scan sequence to reduce motion artifact if available. ECG Gating necessary to assess for aortic root abnormalities or dissection |
| Image quality | Aggressive dose reduction may be used for most indications |

PBF = pulmonary blood flow, systemic BF = systemic blood flow.

*3.3.1.2. Aortic arch abnormalities.* A contrast bolus timed to aortic opacification is ideal for aortic arch imaging. In the neonate with a severe left sided obstructive lesion, the aorta may fill directly from the pulmonary artery through a patent ductus arteriosus. Depending on the lesion, there may be retrograde filling of the ascending aorta, anterograde filling of the descending aorta through the PDA, or both. In these cases, image acquisition can be timed to either the pulmonary artery or descending aorta, whichever is seen most clearly on the monitoring sequence.

*3.3.1.3. Vascular rings/slings.* A pulmonary sling will fill with the pulmonary artery. All other vascular rings are aortic in origin and so should be imaged as a systemic arterial scan. If there is a question of respiratory compromise from cardiac motion or from a vascular anomaly, a low dose multi-phase scan done while the patient is free breathing may allow for a physiologic airway evaluation by simultaneously visualizing both the airway and vasculature during the cardiac and respiratory cycle.[42]

*3.3.1.4. Aortic root abnormalities.* Aortic root abnormalities and the proximal ascending aorta are best visualized with a prospectively ECG-triggered or retrospectively ECG gated scan. Although a bicuspid valve may be visible during any phase of the cardiac cycle, it is best seen in systole or with a functional scan. A non-ECG gated scan of the ascending aorta may result in systolic motion artifact that may mimic type A dissection and does not allow an accurate measurement of the proximal ascending aorta. Even without artifact, there can be a considerable difference in aortic root and ascending aorta size between systole and diastole. It may be useful to report the phase of the cardiac cycle for comparison to measurements made with other modalities when an ECG gated scan sequence is used and to also note if the measurement is made from the inner edge or includes the vessel wall.

*3.3.1.5. Pulmonary arterial abnormalities.* Timing of opacification of the pulmonary arteries will depend on the source of pulmonary blood supply. For a normal circulation, the image acquisition should be timed to filling of the pulmonary arteries, or to the aorta if a longer contrast injection is used (see triphasic or biventricular contrast injection protocols above). In neonatal lesions with pulmonary atresia or severe pulmonary stenosis, the pulmonary flow may originate from the ductus arteriosus or a systemic to pulmonary shunt (e.g. BT shunt), and will fill with the systemic arterial bolus.

### 3.3.2. Thoracic venous abnormalities

*3.3.2.1. Pulmonary venous anomalies.* Optimal opacification of pulmonary venous anomalies is obtained by timing image acquisition to either the PA or left atrium. If the pulmonary veins are obstructed, they may opacify later than expected. In this scenario, a longer contrast injection with later image acquisition or a delayed scan may be necessary. This is particularly important with mixed total anomalous pulmonary venous return (TAPVR) or partial anomalous pulmonary venous return (PAPVR), where there may be different rates of egress from the individual pulmonary veins. The scan range should be adjusted to include the probable area of pulmonary venous return, and should include the thoracic descending aorta to the level of the diaphragm if sequestration is suspected (Scimitar syndrome). If infra-diaphragmatic TAPVR is suspected, the scan range should include the upper abdomen. For suspected supra-cardiac and cardiac PAPVR AND TAPVR, scanning past the diaphragm may not be necessary (Table 6).

*3.3.2.2. Systemic venous anomalies.* Venous imaging can be performed with a venous two-phase contrast bolus, with a longer contrast injection with late image acquisition, or with a delayed scan (Table 7). The timing of venous recirculation is dependent on the size of the patient, cardiac output, filling pressures, and intracardiac shunting. When needed, a delayed venous scan is usually performed 30–60 s after the initial scan. If a patient has poor cardiac output, higher filling pressures, adequate venous opacification may take 120 s or longer. Superior central venous anatomy will be visualized earlier than the lower central venous system (IVC). Some authors advise a higher contrast load for optimal venous imaging that depends on recirculation, particularly in large patients and in those needing IVC visualization (single ventricle imaging is discussed separately).

**Table 6**
Scan modifications for pulmonary venous anomalies.

| Patient preparation | Standard preparation |
|---|---|
| Contrast/Acquisition timing | Timed to PA or LA/LV<br>• Longer injection or later acquisition for mixed or obstructed PAPVR AND TAPVR |
| Scan range | Thoracic inlet to diaphragm<br>• Include upper abdomen if infra-diaphragmatic PV return or pulmonary sequestration |
| Scan sequence | ECG gating not necessary. Use high pitch or volumetric scan mode to reduce motion artifact if available |
| Image quality | Aggressive dose reduction may be used for most indications |

TAPVR – total anomalous pulmonary venous return, PAPVR – partial anomalous pulmonary venous return.

**Table 7**
Scan modifications for systemic venous abnormalities.

| Patient preparation | Standard preparation |
|---|---|
| Contrast/Acquisition timing | • Venous two-phase bolus with acquisition timed to the “arterial” phase<br>• Longer injection and later image acquisition<br>• A delayed (“venous phase”) scan |
| Scan range | Thoracic inlet to diaphragm<br>• Include upper abdomen if IVC definition needed |
| Scan sequence | ECG gating not necessary. Use high pitch or volumetric scan mode to reduce motion artifact if available |
| Image quality | Aggressive dose reduction may be used for most indications |

### 3.4. Coronary artery imaging in pediatric patients

There are many excellent articles outlining optimal CT techniques for coronary artery imaging. Pediatric coronary imaging is often challenging due to higher heart rates and pronounced sinus arrhythmia. Beta blockade should be considered when distal coronary anatomy is needed or lesions are suspected (e.g. Kawasaki disease or symptomatic patient after the arterial switch). Beta blockade in pediatric patients will generally decrease both the heart rate and the respiratory variability.[27,28] Starting the breath hold several seconds earlier in patients with marked sinus arrhythmia (when the contrast is in the PA) will often minimize HR variability during the scan. For many CHD indications, the proximal coronary artery course is most critical and higher heart rates are tolerated. Scanners with the best temporal resolution are most likely to achieve diagnostic images in patients with the highest heart rates (Table 8, Fig. 1).

Patients with steady heart rates below 60–65 bpm can be scanned in diastole with a narrow acquisition window or with a prospectively ECG triggered high pitch helical scan. Patients with higher heart rates should be scanned during systole with a narrow acquisition window on either a retrospectively or prospectively ECG triggered scan.[43] If there is significant heart rate variability, a widened acquisition window or prospective millisecond scanning (at end systole) should be used. For coronary anomalies, the location, ostial anatomy, angulation from the aortic root, proximal course (e.g. interarterial, retroaortic, etc.), presence of an intramural segment, and coronary dominance should be included in the report.

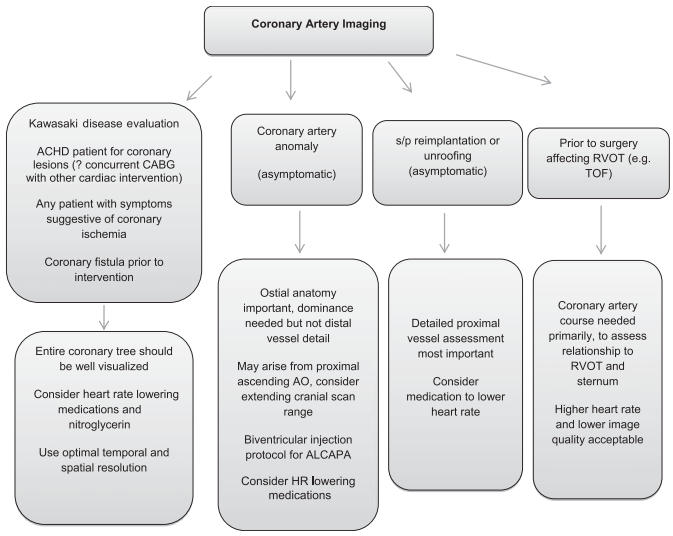


**Fig. 1.** Coronary artery imaging.

**Table 8**
Coronary artery imaging.

| | |
|---|---|
| **Potential indications for coronary artery imaging in CHD** | |
| • Evaluation of coronary artery anomaly in isolation or in combination with other CHD | |
| • Evaluation of coronary artery patency after surgical reimplantation or unroofing | |
| • Evaluation of coronary artery course in relation to the RVOT and sternum prior to repeat intervention | |
| • Adult ACHD patient requiring evaluation of coronary artery for lesions prior to other cardiac intervention (determine need for concurrent coronary artery intervention) | |
| • Patient with a history of Kawsaki disease for assessment of lesion or aneurysm | |
| • Definition of coronary artery fistula prior to intervention | |
| • CHD patient with symptoms suggestive of ischemia and a history of coronary artery intervention | |
| **Scan modifications for coronary artery imaging in pediatric patients** | |
| Patient preparation | • Consider heart rate lowering medications and/or nitroglycerin for detailed coronary imaging of the entire coronary tree (evaluation for potential coronary artery lesions) |
| | • For coronary arterial course and proximal anatomy only, higher heart rates may be tolerated |
| | • Most scan sequences used for detailed coronary artery imaging require a breathhold |
| | • Consider breathing the patient early (with contrast in the pulmonary artery) to decrease the heart rate variability during monitoring and acquisition. This is only helpful if the patient can tolerate the longer breath required |
| Contrast/Acquisition timing | • Standard dual phase contrast injection for isolated coronary imaging with scan acquisition timed to the aorta |
| | • Biventricular contrast injection protocol for patients with both right and left heart pathology requiring coronary artery imaging (s/p arterial switch, Ross procedure, Nikaidoh, Truncus arteriosus repair) or for evaluation of a coronary artery from the pulmonary artery. High density contrast in the right ventricle may cause artifact in the area of the mid right coronary artery |
| Scan range | • Cardiac silhouette for standard coronary artery imaging |
| | • Anomalous coronary arteries may arise from the proximal ascending aorta, superior scan range should be extended for this indication |
| | • Scan range should include the pulmonary arteries after RVOT intervention or pulmonary conduit placement |
| Scan sequence | • Retrospectively ECG gated or prospectively ECG triggered depending on heart rate |
| | • Prospective millisecond scanning may be used if there is significant arrhythmia and heart rate variability despite pre-medication |
| | • Acquisition window should be timed to end systole or diastole depending on heart rate |
| | • Use the narrowest acquisition window possible based on heart rate, particularly if detailed and high resolution coronary imaging is not needed |
| Image quality | • For definition of coronary artery lesions, high spatial and temporal resolution is needed |
| | • For definition of coronary arterial course, higher heat rate and lower radiation dose is tolerated and aggressive dose reduction may be used |

### 3.5. Functional imaging: quantification of ventricular function, valvular regurgitation, prosthetic valve evaluation

Echocardiography is the first line imaging modality for estimation of function in CHD, but is not reproducible for single and right ventricles; and many older patients have poor acoustic windows due to sternal scar or obesity.[44–46] Functional imaging in CHD is most commonly performed by MRI but CT may be used in patients with artifact on MRI or devices contraindicated for MRI.[46–48] Functional CT imaging should be reserved for those in whom it will affect clinical management.

A retrospectively ECG gated CT scan with radiation delivered throughout the cardiac cycle can be reconstructed in multiple phases to allow estimation of end-systolic and end-diastolic volumes and calculation of ejection fraction. Most sequences will deliver full radiation for a portion of the cardiac cycle (acquisition window), and approximately 20% of full radiation through the remainder of the cardiac cycle to decrease radiation exposure (commonly called "ECG-based tube current modulation"). The fully radiated portion of the cardiac cycle can be set for either end-systole or end-diastole depending on the clinical indication. Certain CT scanners allow for ventricular volume and ejection fraction determination using either prospective ECG-triggered or retrospective ECG gated sequences. While some post-processing software packages allow semi-automated calculation of ventricular volumes and function directly from a standard CT dataset, most experts reconstruct the dataset in 6–8 mm short axis slices for manual tracing in CHD patients. For this reason, improved signal to noise gained from the reconstruction with thick slices may be allow for much noisier images and lower radiation doses to be acceptable without lowering the accuracy of the measurement of ejection fraction.[49,50] For functional imaging, beta blockade is not typically required unless high resolution coronary artery imaging is also needed from the fully radiated phase of the dataset. For estimation of right ventricular function, a biventricular injection protocol should be used so that the endocardial borders of the right ventricle are clearly defined.[51–57]

A functional CT dataset can be used for evaluation of native and mechanical valve stenosis and insufficiency, perivalvular leak, thrombosis, abscess and endocarditis.[58–65] Stroke volume differences between ventricles calculated from a functional dataset may be used to quantify valvular regurgitation or cardiac shunt if correlated closely with echocardiographic findings.[66,67] The reproducibility of RV function assessment is more variable and time consuming that assessment of LV function, however, and reproducibility is dependent on observer experience. For this reason, caution and careful consideration must be used with this approach and it has not been validated in the pediatric age range.[68] Estimation of regurgitation is not possible in single ventricle patients, and in patients with more than one regurgitant lesion or intracardiac shunt, only the total difference in stroke volume is evaluable, with reliance on other modalities for assessment of the contribution of each lesion.[47,48,55,57] Careful correlation to echocardiography should be used when interpreting stroke volume differences to determine valvular regurgitation since flow sequences cannot be used to verify findings as in CMR (Table 9).

**Table 9**
Functional analysis in CHD.

| | |
|---|---|
| **Common indications for functional analysis in CHD** | |
| • Quantification of right ventricular volumes and ejection fraction to determine the optimal timing of surgical or transcatheter pulmonary valve placement in patients with pulmonary stenosis or insufficiency and echocardiographic evidence of right ventricular enlargement or dysfunction (s/p TOF or any surgery requiring placement of a pulmonary artery conduit) | |
| • Calculation of ejection fraction for patients with echocardiographic evidence of systemic ventricular systolic dysfunction (single ventricle, systemic right or left ventricle) to guide medical management of heart failure, placement of EP devices, and advanced heart therapies (VAD, transplant)[3] | |
| • Evaluation of ejection fraction and ventricular dyssynchrony in pacemaker dependent patients to determine need for biventricular pacing and to guide optimal lead placement (concomitant coronary sinus imaging is important for these cases)[3,69] | |
| • Evaluation of prosthetic valve function in patients with unexplained systolic gradient, for evaluation of paravalvular leak or possible mass/vegetation (clot/endocarditis) | |
| • Evaluation of complex AV valve attachments in subarterial obstruction, after AV canal defect, corrected transposition, s/p Rastelli etc. | |
| • Calculation of stroke volume difference to estimate regurgitation if correlated closely with echocardiography (only possible in biventricular circulation). If more than one regurgitant lesion or shunt, only the total stroke volume difference can be reported and echocardiography must be used to determine severity of individual lesions | |
| **Scan modifications for function analysis** | |
| Patient preparation | Consider heart rate lowering medications and/or nitroglycerin only if detailed coronary imaging needed from the fully radiated phase of the functional dataset |
| Contrast/Acquisition timing | • Standard injection for left or single ventricle function<br>• Biventricular injection protocol for right and left ventricular function, particularly if stroke volume differences are used to assess valvular regurgitation.<br>• Dual phase venous injection if function and anatomy needed in single ventricle physiology |
| Scan range | • Cardiac silhouette |
| Scan sequence | • Retrospectively ECG gated or prospectively ECG triggered<br>• ECG pulsed tube current with full current only in end systole or diastole depending on indication and heart rate (ECG-based tube current modulation)<br>• Narrow acquisition window if detailed and high resolution coronary imaging not needed<br>• use lower kVp if 6–8 mm data sets will be used for reconstruction |
| Image quality | • quantification most commonly performed in 6–8 mm slices, aggressive dose reduction may be used unless high resolution intracardiac anatomy valve detail is needed (for example mechanism of valve regurgitation) |

### 3.6. By most commonly referred diagnosis

#### 3.6.1. Aortic arch anomalies

For recommendations on contrast injection and scan acquisition details, see thoracic arterial imaging above (Table 10).

**Table 10**
Aortic Arch Imaging in CHD.

| | |
|---|---|
| **Common residual hemodynamic lesions or reasons for re-intervention**: | |
| Aortic coarctation | Recurrent aortic arch obstruction |
| | Aortic aneurysm or pseudo aneurysm |
| | Aortic dissection |
| | In stent stenosis |
| | Ascending aortic dilation |
| | Bicuspid aortic valve |
| Interrupted aortic arch | Recurrent obstruction of arch or tube graft |
| | Aneurysm or pseudo aneurysm |
| Connective tissue disorder | Marfan/Loeys–Dietz syndrome: |
| | Arterial tortuosity |
| | Aortic dilation or aneurysm |
| | Aortic dissection |
| | Williams syndrome |
| | Progressive aortic or pulmonary arteriopathy and stenosis |
| | Supravalvular aortic stenosis |
| | Coronary ostial narrowing |
| | Turners syndrome |
| | Bicuspid aortic valve |
| | Aortic dilation (index aortic size to body surface area) |
| | Aortic coarctation |
| **Scan modifications**: | |
| Patient preparation | Consider heart rate lowering medication and nitroglycerin if detailed coronary artery definition needed |
| Contrast/Acquisition timing | Single phase arterial bolus unless other CHD lesions are present |
| | Biventricular injection protocol: |
| | • Williams syndrome, should include pulmonary arteries |
| | • s/p Ross procedure (assess RVOT conduit, neo-aorta, reimplanted coronary arteries) |
| Scan range | • Thoracic inlet to diaphragm, consider slightly higher range for Loeys–Dietz syndrome to assess neck vessel tortuosity |
| | • Consider including renal arteries if Williams syndrome and hypertension |
| | • Include abdominal descending aorta for mid-aortic syndrome |
| Scan sequence | • DAO anatomy only: ECG gating not necessary. Use high pitch or volumetric scan mode to reduce motion artifact if available |
| | • AAO or coronaries needed: ECG triggered/gated |
| | • Function indicated: ECG triggered/gated with pulsed radiation if estimation of function or valve regurgitation needed |
| Image quality | • May use aggressive dose reduction unless detailed coronary imaging is needed |

#### 3.6.2. Tetralogy of Fallot

For a complete review of the use of CT imaging in patients with Tetralogy of Fallot, please refer to the part 1 consensus document. CT imaging has been described for complete preoperative and postoperative evaluation of patients with all forms of tetralogy of Fallot (Table 11, Fig. 2).

*3.6.2.1. Tetralogy of Fallot – preoperative evaluation.* CTA is primarily used for definition of aortopumonary collaterals or pulmonary arteries in the setting of pulmonary atresia or severe pulmonary stenosis. With either of these, there will be mixing through the VSD, so the scan should be timed from aortic opacification. Use an ECG gated/triggered sequence if a coronary anomaly is suspected. In particular, attention should be drawn to any major coronary crossing the right ventricular outflow tract that will affect surgical approach and ability to place transannular patch when needed (such as a dual left anterior descending coronary, which is more common with this lesion).

*3.6.2.2. Tetralogy of Fallot – early postoperative evaluation.* CT may be used for evaluation of an aorto-pulmonary shunt (e.g. BT shunt) for those who have undergone interval palliation prior to repair; evaluation of main and branch PA anatomy after compete repair. As with the preoperative evaluation, when there is an open VSD and shunt-dependent pulmonary blood flow, the scan should be timed to aortic opacification. For those who have undergone a complete repair, a biventricular contrast injection should be used to opacify both the pulmonary arteries and the aorta. Use an ECG gated/triggered sequence if coronary artery evaluation or ventricular function is needed.

*3.6.2.3. Tetralogy of Fallot – late postoperative evaluation.* A biventricular injection protocol should be used. In these patients, it is generally necessary to define the right ventricular outflow tract (RVOT) in addition to the pulmonary arteries (PAs). It is also important to define the coronary artery relationship to the RVOT prior to valve replacement, along with the relationship between the sternum and vascular structures (coronaries, PAs, aorta) in preparation for repeat sternotomy. Aortic root dimensions should be documented as well, since they are increased in a majority of patients. Stroke volume differences to estimate regurgitation has been reported with adequate correlation to MRI.[47,66] Many post-operative patients will additionally have left ventricular dysfunction.

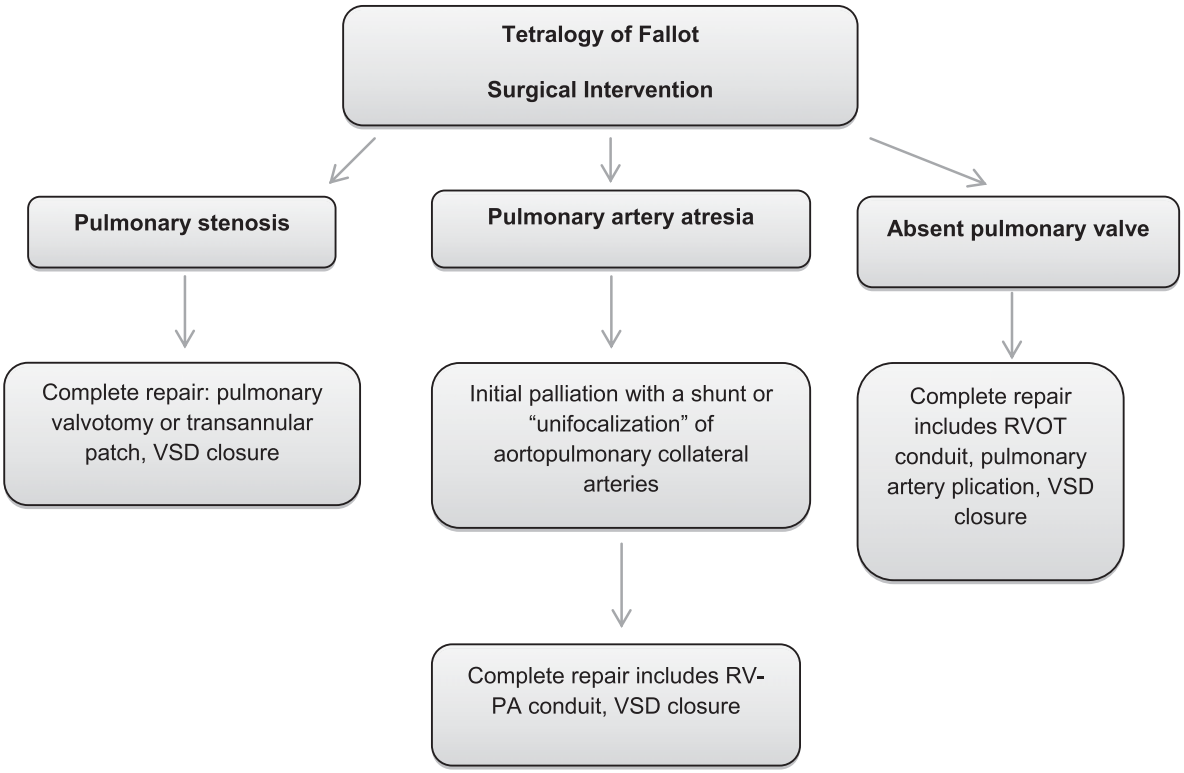


**Fig. 2.** Tetralogy of Fallot and surgical intervention.

**Table 11**
TOF after complete repair.

| | |
|---|---|
| **Common residual hemodynamic lesions or reasons for re-intervention**: | |
| TOF – PS: | Main and branch pulmonary artery stenosis<br>Pulmonary insufficiency<br>RV dilation and dysfunction<br>Tricuspid regurgitation<br>Aortic root dilation |
| TOF – PA: | RV-PA conduit obstruction and insufficiency<br>Branch or distal PA stenosis<br>RV dilation and dysfunction<br>Tricuspid regurgitation<br>Aortic root dilation |
| TOF – absent pulmonary valve: | Branch pulmonary artery dilation<br>RV-PA conduit stenosis or insufficiency<br>Airway abnormalities or external compression from PA<br>RV dilation and dysfunction<br>Tricuspid regurgitation<br>Aortic root dilation |
| **Scan modifications**: | |
| Patient preparation | • Heart rate lowering medication and coronary vasodilators if older patient requiring high resolution coronary imaging to assess for lesions (symptomatic or prior to intervention to assess need for coronary revascularization)<br>• The origin and course of the proximal coronaries (relationship to sternum and RVOT) are most important in younger patients prior to re-intervention. A higher heart rate and lower resolution dataset tolerated and beta blockade is usually not required |
| Contrast/Acquisition timing | • VSD open & RVOT obstruction: bolus with acquisition timed to either branch pulmonary artery or aortic opacification (should be near simultaneous)<br>• VSD repaired: biventricular injection protocol |
| Scan range | • Thoracic inlet to diaphragm |
| Scan sequence | • PA anatomy only: ECG gating not necessary. Use high pitch or volumetric scan mode to reduce motion artifact if available<br>• Coronaries needed: ECG triggered/gated<br>• Function indicated: ECG triggered/gated with pulsed radiation if estimation of function or pulmonary regurgitation needed |
| Image quality | • May use aggressive dose reduction unless high resolution coronary anatomy is needed |

*3.6.3. Transposition of the great arteries*

Transposition of the great arteries describes a complex group of cardiac anomalies. For a complete review of the use of CT imaging in patients with all forms of transposition complexes, please refer to the part 1 consensus document. CT imaging has been described for complete pre-operative and postoperative evaluation of patients with all forms of transposition of the great arteries (Table 12, Fig. 3).

*3.6.3.1. d-TGA preoperative evaluation.* Advanced imaging is usually not needed unless significant aorticpulmonary size discrepancy, unusual aortic-pulmonary orientation or coronary anomaly. The timing of great artery opacification will depend on the amount of mixing at the atrial, ventricular, or ductal level. A biventricular injection protocol or longer injection should be used to optimally opacify both the aorta and pulmonary arteries.

*3.6.3.2. d-TGA postoperative evaluation.* CT has be used to assess atrial baffles after the atrial switch, the neopulmonary and aortic root and coronary artery anastamosis after the arterial switch. See part 1 document for a detailed review. A biventricular injection protocol should be used. The coronary imaging resolution required will vary depending on clinical situation.

*3.6.3.4. Complex transposition.* Complex transposition describes transposition complexes with associated cardiac defects and/or significant aortic or pulmonary stenosis. These patients typically requiring Nikaidoh, Rastelli, single ventricle palliation or arterial switch with correction of other abormalites. A biventricular injection protocol should be used and coronary resolution required will vary depending on clinical situation (see Table 13).

*3.6.3.5. Congenitally corrected transposition.* CC-TGA has a high rate of heart block and pacemaker insertion and so is a relatively common indication for cardiac CT despite it's rarity. Systemic AV valve (tricuspid) abnormalites and regurgitation are common (see Table 14).

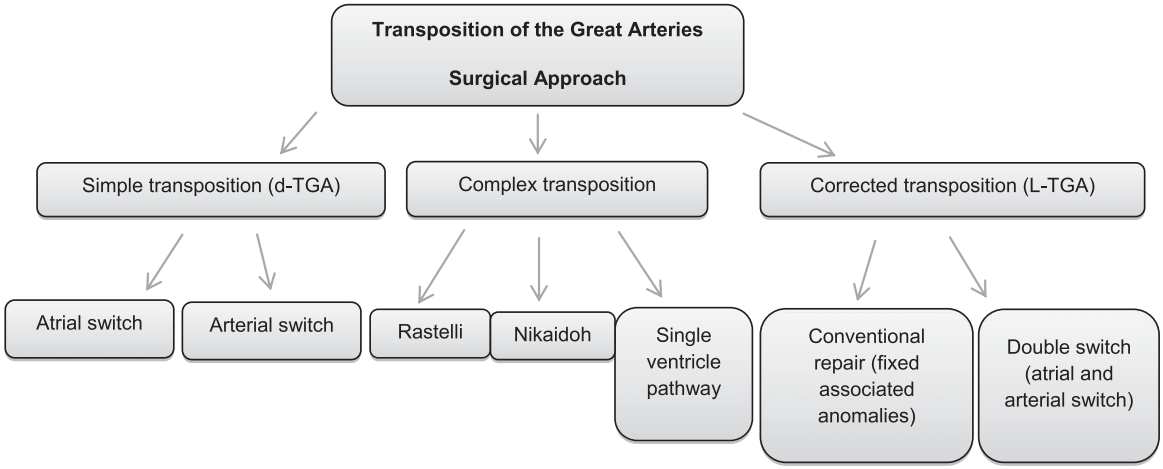


**Fig. 3.** Transposition of the great arteries and surgical approach.

**Table 12**
D-TGA after s/p atrial switch and s/p arterial switch.

| **D-TGA after atrial switch (Senning or Mustard)** | |
|---|---|
| **Common residual lesions or indications for intervention after the atrial switch**: | |
| Systemic or pulmonary venous baffle narrowing or leak | |
| RV failure (systemic ventricle) | |
| Subpulmonary obstruction due to ventricular septal shift into the outflow tract | |
| Tricuspid regurgitation | |
| Heart block relatively more common than other CHD lesions | |
| **Scan modifications**: | |
| Patient preparation | Consider heart rate lowering medication and coronary vasodilators if patient is older or has symptoms suggestive of ischemia and requires detailed coronary imaging |
| Contrast/Acquisition timing | • Biventricular injection protocol with acquisition timed to aortic opacification<br>• Consider routinely lengthening the monitoring sequence and the contrast injection. SVC baffle obstruction is common, and the heart may fill via collaterals<br>• Consider performing a delayed scan if high likelihood of baffle obstruction (particularly important for an SVC obstruction if an upper extremity IV is used). Beam hardening may make detailed venous imaging difficult to interpret if stenosis and/or stents are present |
| Scan range | • thoracic inlet to diaphragm |
| Scan sequence | • Baffle anatomy only: ECG gating not necessary. Use high pitch or volumetric scan mode to reduce motion artifact, if available<br>• Coronaries needed: ECG triggered/gated |

(*continued on next page*)

**Table 12** (*continued*)

| **D-TGA after atrial switch (Senning or Mustard)** | |
|---|---|
| | • Function indicated: ECG triggered/gated with pulsed radiation if estimation of function or tricuspid regurgitation needed<br>• Consider delayed venous scan if high likelihood of systemic venous obstruction |
| **D-TGA s/p arterial switch** | |
| **Common residual lesions or reasons for intervention**: | |
| Neo-pulmonary root or branch pulmonary artery stenosis | |
| Neo-pulmonary insufficiency | |
| Neo-aortic root dilation, stenosis or insufficiency | |
| Ostial stenosis of re-implanted coronary arteries | |
| **Scan modifications**: | |
| Patient preparation | Consider heart rate lowering medication and coronary vasodilators if detailed coronary imaging needed |
| Contrast/Acquisition timing | Biventricular injection protocol |
| Scan range | Include cardiac silhouette and branch pulmonary arteries |
| Scan sequence | High pitch or volumetric scan mode to reduce motion if available<br>• Non ECG gated on standard pitch scanners<br>• ECG triggered/gated if coronary or aortic root imaging needed |
| Image quality acceptable | • High resolution coronary ostial imaging needed at least once during adolescence or early adulthood and for symptomatic patients<br>• Optimal temporal and spatial resolution needed for coronary scans. If scan is primarily for evaluation of the neo-pulmonary root prior to intervention, optimal image quality is not needed and scanner output may be aggressively reduced |

**Table 13**
Complex repair of transposition (Raselli, Nikaidoh).

| | |
|---|---|
| **Common residual hemodynamic lesions and indication for reintervention**: | |
| After Rastelli: | |
| Obstruction of the RV-PA conduit or branch pulmonary arteries, pulmonary conduit insufficiency | |
| The coronary arteries are usually not manipulated in the Rastelli, but the coronary relationship to the RVOT conduit and sternum needs to be defined prior to repeat intervention | |
| LV-AO obstruction from the VSD patch is also relatively common in DORV | |
| After Nikaidoh: | |
| RVOT or RV-PA conduit stenosis or insufficiency | |
| The right coronary artery is at risk for lesions in the mid vessel due to the stretching at the time of aortic translocation | |
| **Scan modifications**: | |
| Patient preparation | Consider heart rate lowering medication and coronary vasodilators if coronary artery imaging needed |
| Contrast/Acquisition timing | Biventricular injection protocol |
| Scan range | Cardiac scan range to upper thorax to include branch pulmonary arteries |
| Scan sequence | • High pitch or volumetric scan to reduce motion if available<br>• Non ECG gated on standard pitch scanners, unless coronary imaging or intracardiac anatomy needed |
| Image quality acceptable | • Optimal temporal and spatial resolution needed for high resolution coronary scans in patients after reimplantation (at least once in adolescence or adulthood) or if symptoms suggestive of ischemia<br>• If scan is primarily for evaluation of the neo-pulmonary root, LV-aortic pathway prior to intervention, optimal image quality is not needed and scanner output may be aggressively reduced |

**Table 14**
Congenitally corrected TGA.

| | |
|---|---|
| **Common residual hemodynamic lesions and indication for reintervention**: | |
| Double switch: see atrial and arterial switch complications and need for reintervention above | |
| No intervention: systemic RV failure and tricuspid regurgitation common, ventricular septal shift into left ventricle causing subpulmonary obstruction | |
| All patients: risk of complete heart block is approximately 2% per year | |
| **Scan modifications**: | |
| Patient preparation | Standard preparation |
| Contrast/Acquisition timing | Biventricular injection protocol<br>Slightly elongated injection phase (4–5 s longer) with resultant delay in acquisition if coronary sinus definition needed prior to EP procedure |
| Scan range | • Include pulmonary arteries<br>• Include systemic venous system if EP procedure planned |
| Scan sequence | • High pitch or volumetric scan mode for anatomy<br>• Retrospectively ECG gated or prospectively ECG-triggered for functional analysis |
| Image quality acceptable | Detailed coronary imaging usually not needed and scanner output can be aggressively reduced |

*3.6.4. Single ventricle heart disease*

For a complete review of the use of CT imaging in patients with single ventricle heart disease, please refer to the part 1 consensus document. CT imaging has been described for complete preoperative and postoperative evaluation of patients through all forms of single ventricle palliation (Table 15, Fig. 4).

*3.6.4.1. Prior to stage 1 (pre-Norwood or shunt).* Advanced imaging is performed in a minority of patients to define venous or arterial abnormalities (notably those with atrial isomerism/heterotaxy), and image acquisition should be timed for area of interest. There is complete mixing at the atrial level, and ductal-dependent systemic or pulmonary blood flow is very common and when present, the pulmonary arteries and aorta will opacify simultaneously. Intracardiac and ductal shunting is nearly universal, so air emboli precautions should be taken.

*3.6.4.2. Between stage 1 and 2 (S/p Norwood or Sano).* The goal of imaging is for simultaneous venous and arterial opacification by using a long injection and relatively late acquisition. Upper venous anatomy will opacify prior to the IVC due to the relatively larger head to body surface area in small children and the shorter transit time. Pulmonary blood flow is shunt-dependent, so the pulmonary arteries will opacify immediately from the aorta. If there is high likelihood of upper central venous obstruction or IVC anomaly, consider a delayed image acquisition that relies on venous recirculation to visualize the superior venous anatomy without streak artifact from dense contrast injection. Alternatively, one could inject contrast from a lower extremity IV. Intracardiac shunting is nearly universal, so air embolus precautions should be used.

*3.6.4.3. Between stage 2 and 3 (s/p superior cavo-pulmonary anastamosis (Glenn or Hemi-Fontan).* Upper extremity contrast injection will directly opacify the pulmonary arteries through the SVC-PA anastamosis. Incomplete mixing of contrast, aorto-pulmonary collaterals, and bilateral superior vena cavae will result in differential branch pulmonary artery opacification. Opacification of veno-venous collaterals is dependent on IV location. The timing of ventricular and arterial opacification will depend on ventricular diastolic pressure, ventricular function, and AV valve regurgitation, and is variable. A venous two-phase injection, slow contrast injection with late image acquisition, or a second image acquisition is sometimes needed to obtain both a diagnostic central venous and arterial scan. Intracardiac shunting is generally present, so air emboli precautions should be taken (Table 16).

*3.6.4.4. After stage 3 (s/p Fontan).* Imaging after the Fontan procedure is complex. Given the passive filling of the pulmonary circulation and the frequent presence of venous obstruction, the monitoring sequence should be extended for potential late cardiac filling through collateral vessels. If the primary clinical question involves the aortic arch, intracardiac anatomy or ventricular function, one can bolus track on the aorta using the appropriate acquisition protocol. Opacification of the Fontan circuit is challenging due to differential streaming of contrast into the pulmonary arteries, incomplete mixing in the Fontan circuit, and differential timing of opacification of the superior and inferior central venous system. Unexpected venous occlusion and veno-veno or veno-arerial collateral vessels are also common findings in single ventricle patients and make contrast timing difficult to predict. Various strategies have been proposed to overcome these limitations. In general, one should consider using a larger amount of contrast (2.5 ml/kg up to 150 ml). Some authors[70] advocate a single acquisition in the venous phase, using a delay of 60–150 s after initiation of contrast injection. While this provides the most homogenous opacification and generally allows for identification of clots, the relatively low Hounsfield units limit image quality and is inadequate for coronary imaging. Additionally, the considerable variability in patient hemodynamics makes acquisition timing difficult. Image acquisition should be delayed even longer than normal in the presence of an atriopulmonary Fontan, significant ventricular dysfunction or severe AV valve regurgitation. A venous two-phase contrast protocol (as described in previous sections, but using 50% of the contrast in the first phase) will allow opacification of the entire Fontan circuit. However, since the opacification will not be homogeneous a 2nd scan in the venous phase will be necessary to more definitively evaluate for a thrombus in the Fontan circuit. Other authors[71] recommend simultaneous injection in lower and upper extremity veins. While this often results in adequate opacification in patients with laminar Fontan flow, most patients will still have swirling, unopacified hepatic venous inflow, or incomplete mixing necessitating a second scan in the venous phase. Additionally the superior portion of the Fontan usually fills earlier than the inferior portion, and even with simultaneous injection there may be unequal opacification of the Fontan circuit, particularly if bilateral superior vena cavae are present (Table 17).

With either of the latter two imaging approaches, consider a lower-dose functional scan if a second acquisition is needed. Often, low kV functional (multi-phase) imaging will allow visualization of contrast streaming and can rule out a clot vs venous admixture better than a single cardiac phase acquisition. Evaluation of Fontan anatomy is one of the only indications where most authors perform a routine delayed scan. Dual energy scanning[72] has been shown to be useful in this population when screening for thrombus formation.

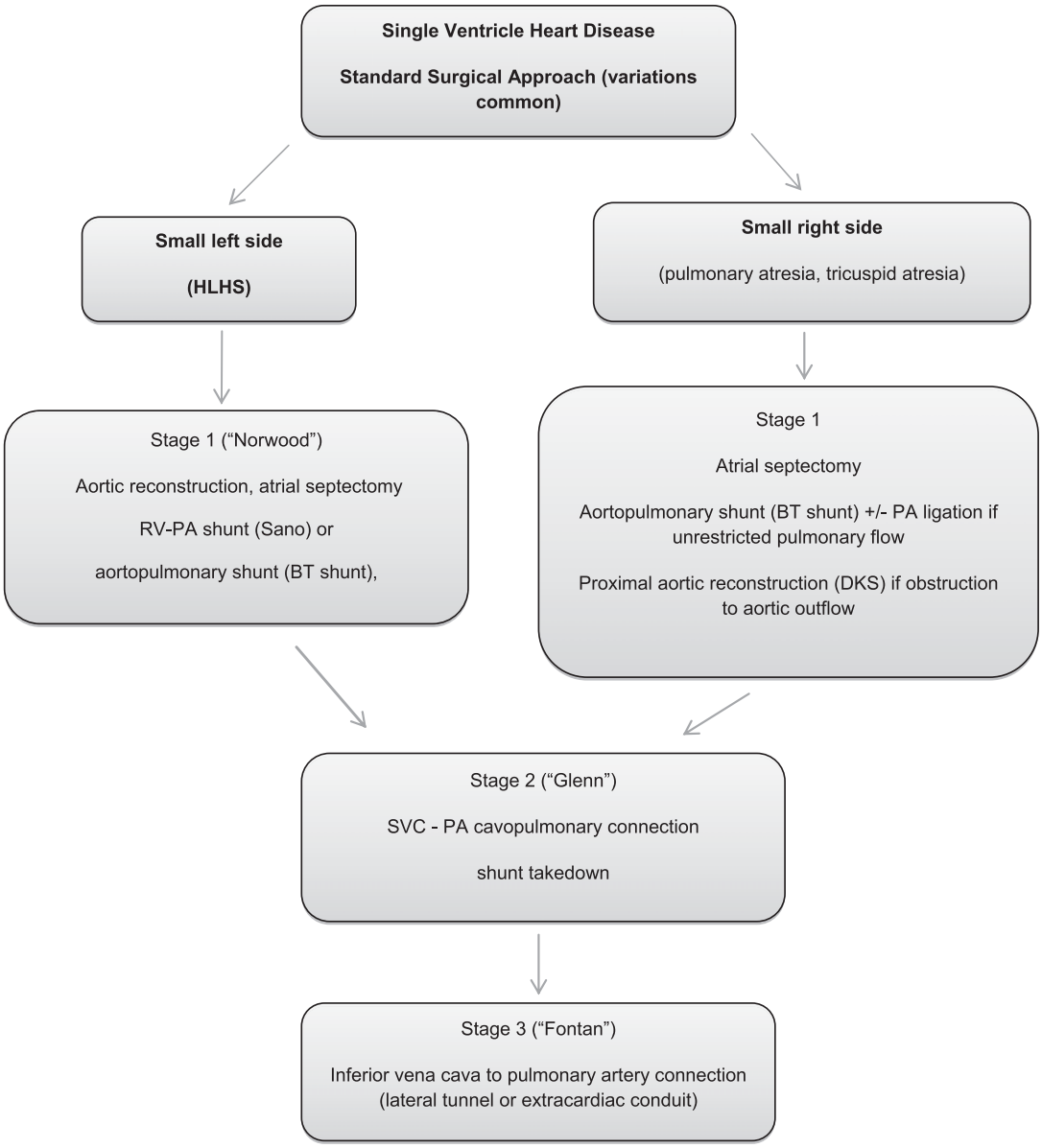


**Fig. 4.** Standard surgical approach in single ventricle heart disease.

**Table 15**
Single ventricle heart disease between stage 1 and 2.

| | |
|---|---|
| **Common residual hemodynamic and anatomic lesions**: | |
| Shunt or branch pulmonary artery stenosis or thrombosis | |
| Residual coarctation/distal arch narrowing (HLHS) | |
| Systemic venous occlusion or collaterals, and aortic/bronchial collateral | |
| Single ventricle dysfunction or valvular regurgitation (regurgitation cannot be quantified by CT) | |
| **Scan modifications**: | |
| Patient preparation | Consider lower vs upper extremity IV, as discussed above |
| Contrast/Acquisition timing | Give long bolus with late image initiation to opacify central venous system and arterial anatomy in same acquisition. |
| Scan range | Thoracic inlet to diaphragm |
| Scan sequence | High pitch, volumetric or non-ECG triggered |
| Image quality acceptable | Usually large structures; may reduce output |

**Table 16**
Single ventricle heart disease between stage 2 and 3.

| | |
|---|---|
| **Common residual hemodynamic and anatomic lesions after stage 2 single ventricle palliation (Glenn):** | |
| SVC or branch pulmonary artery stenosis or clot | |
| Residual coarctation/distal arch narrowing (HLHS) | |
| Systemic venous occlusion or collaterals | |
| Aorto-pulmonary collateral formation | |
| Single ventricle dysfunction or valvular regurgitation (regurgitation cannot be quantified by CT) | |
| **Scan modifications**: | |
| Patient preparation | Upper extremity IV will directly opacify the pulmonary arteries (SVC connected the PA), unless there are bilateral superior vena cavae |
| Contrast/Acquisition timing | • Incomplete mixing of contrast in branch PAs common; give two phase contrast bolus and time image acquisition to arterial filling, or consider late image acquisition to avoid artifact from high density contrast<br>• Consider 2nd, delayed acquisition if high suspicion of clot formation or systemic venous abnormality suspected |
| Scan range | Thoracic inlet to diaphragm |
| Scan sequence | High pitch or volumetric scan mode when available, or non-ECG triggered |
| Image quality | May use aggressive dose reduction |

**Table 17**
Single ventricle heart disease after stage 3.

| | |
|---|---|
| **Common residual hemodynamic and anatomic lesions after Fontan completion**: | |
| SVC to PA, IVC to PA, or branch pulmonary artery narrowing | |
| Atrial dilation (most commonly in older atriopulmonary types of Fontan) | |
| Systemic venous occlusion, veno-venous collaterals or aorto-pulmonary collaterals | |
| Clot within the Fontan system, pulmonary embolism | |
| Ventricular to aortic obstruction for complex transposition with aorta from an outlet chamber | |
| Ventricular dysfunction or valvular regurgitation (regurgitation can't be quantified by CT) | |
| Recurrent arch obstruction | |
| Fenestration | |
| Baffle leak in lateral tunnel Fontan | |
| Hepatic disease | |
| Plastic bronchitis | |
| **Scan modifications**: | |
| Patient preparation | Upper extremity IV only is most commonly used<br>Consider upper and lower extremity IVs |
| Contrast/Acquisition timing | Contrast (multiple options)<br>• Use 2–2.5 ml/kg contrast, up to 150 ml<br>• Two-phase venous injection protocol, with 50% of the contrast given in the first phase and image acquisition timed to the second phase. Pause of 30 s between contrast injections, increased to up to 60 s if atriopulmonary Fontan, or severely decreased ventricular function<br>• Simultaneous injection in upper and lower extremity veins*<br>Acquisition (multiple options):<br>• Single scan during venous phase, with delay of 60–120 s from contrast injection<br>• Single scan timed to opacification of cardiac structures if using two IVs<br>• Time initial scan to arterial opacification during the second phase of a venous injection protocol<br>• consider a 2nd scan during the venous phase, at least 30–60 s after the first scan<br>• Consider dual energy CT |
| Scan range | • Thoracic inlet to diaphragm<br>• Liver disease common, consider including upper abdomen if liver imaging needed |
| Scan sequence | • High pitch/volumetric or non-ECG triggered, unless coronary imaging needed<br>• Consider low kV functional (multi-phase) scan to allow visualization of venous admixture and contrast streaming (difficult to differentiate from clot on a single phase acquisition) |

## 4. Patient specific radiation reduction techniques

All imaging modalities that utilize radiation must adhere to the "as low as reasonably achievable" (ALARA) concept regarding the delivered dose from the exam. The pertinent parameters that affect radiation exposure from all CT studies are the tube potential (kilovolt peak: kVp), tube current (milliampere-second: mAs), pitch, scan length and slice collimation.[73] For cardiac CT, the sequence used and the width of the acquisition window on an ECG triggered scan additionally affect dose. The lowest dose ECG gated scans will be obtained with a regular and slow heart rate. Higher heart rates often need a wider acquisition window for detailed coronary imaging. The highest doses may be given with irregular heart rate during the scan monitoring phase, as the acquisition window will be automatically widened to capture a diagnostic image.

On most CT scanners, the standard tube potential (kVp) options are 80, 100, or 120. Some vendors offer a 70 kVp and 90 kVp option for small patients and 140 and 150 kVp for the largest patients. Some systems offer an automated tube potential selection which automatically chooses the optimal kVp for each patient based on the topographic image.[74,75] Only one kV is selected for the entire examination.[74] If the scanner chooses a kV higher than is needed by clinician estimate and experience, it should be manually reduced from what is suggested by the automated software. Keeping other factors constant, decreasing the kVp from 120 to 80 can result in up to a 65% dose reduction.[73,76] For cardiac CT in infants and children, tube potential should be reduced to 70 or 80 kVp. Many teenagers and young adults can be imaged with 70 or 80kVp as well, reserving 100 kVp for muscular or mild-moderately overweight patients.[77] There is increased scatter from metallic objects at lower kVp

settings, so this should be considered in choosing the tube potential when there are large metallic prostheses, such as spinal rods, present.

The lowest possible tube current (mAs) for a given tube potential (kV) should be used in cardiac CT. Automatic tube current modulation (or automated exposure control [AEC]) modulates (mAs) based on the topographic (scout) image.[73,78,79] The AEC should maintain fairly constant image noise throughout the exam by varying mAs based on tissue attenuation. This usually results in an overall radiation dose reduction in a normal size patient, but may actually increase the radiation exposure in large patients to maintain acceptable image noise levels. AEC software can reduce radiation dose by up to 40%–50% over standardized imaging algorithms, and is optimized when the patient is centered in the gantry.[79] Patient centering is a key aspect to achieving optimal image quality balanced with radiation dose, and should be communicated strongly to CT Technologist. The image quality considered acceptable may be adjusted prior to image acquisition based on indication (limited, moderate and aggressive mAs reduction factor).[80] As with the automated choice of tube potential, the tube current can be manually decreased from the recommended level if higher noise can be tolerated for a given indication.

Radiation dose is inversely proportional to pitch for some scanner platforms when using helical scan mode.[39] The latest generation of dual-source CT technology (in which dose is independent of pitch) permits scanning at very high pitch values, up to 3.4 because of the presence of two x-ray tubes.[81] In single-source CT, the maximum pitch is limited to 1.5. The hiighest pitch scan modes decrease the time of image acquisition compared to standard pitch scan modes, and, therefore, can also decrease the need for sedation or anesthesia in young patients.[77]

CT radiation dose is directly proportional to the z-axis scan length when all other acquisition parameters are similar, as the Dose Length Product (DLP) = CTDIvol × scan length. It is essential that the scan length be minimized to include only the area of interest to reduce radiation dose. The typical scan length for cardiac CT extends from just below the carina to slightly below the diaphragm. If great vessel or venous anomalies are expected, a longer scan length will be required and will typically include the entire thorax.

Thicker collimation (0.6–0.75 mm) will reduce radiation dose, improve image signal, and decrease image acquisition time. Spatial resolution and visualization of small structures such as the coronary arteries, however, will be reduced. For the highest resolution evaluation of small intracardiac structures or the coronary arteries, the narrowest collimation is indicated. Thicker collimation can be considered when imaging larger structures, or for functional imaging where the dataset is often evaluated in 6–8 mm slices.

Radiation exposure from CT can be minimized by shortening the acquisition window ("padding") on prospectively ECG gated scans.[82] If all other scan parameters are kept constant, increasing the acquisition window is associated with a linear increase in radiation dose.[82] For both retrospectively and prospectively ECG gated scans, the percentage of the R-R interval with full radiation can be narrowed to a single cardiac phase. The minimal acquisition window that will provide the necessary information based on indication and heart rate should be used. Some scanners offer automatic windowing to optimize the window and reduce the radiation dose to the patient based on patient-specific ECGs.

The use of iterative reconstruction results in improved image quality with standard scanner output, or with lower radiation doses without loss of image quality if the scanner output is prospectively decreased. Multiple studies using different vendors' equipment have shown decreases in radiation dose up to 40%–50%.[83,84] Prospectively decreasing scanner output when iterative reconstruction is available is recommended.[85]

### 4.1. Reporting of scanner output

#### 4.1.1. DLP and CTDIvol

The most widely used parameters of scanner output are CT dose index volume (CTDIvol) and dose length product (DLP). The CTDIvol reflects the average absorbed dose in a CT phantom and is reported in milligray (mGy). The CTDIvol multiplied by the length of the scan is the DLP which is reported in mGy-cm.[86,87] CTDIvol and DLP are estimated for standard size cylindrical phantoms (16 cm and 32 cm diameter). The absorbed dose in a 16 cm phantom is approximately 2.2 times higher than that listed for a 32 cm phantom. Prior to 2014 some vendors listed CTDIvol and DLP based on a 16 cm phantom for body exams for children less than 18 months or 12 years of age. In 2012, the FDA and IEC clarified that CTDI (and so DLP) should be displayed for the 32 cm (320 mm) CTDI phantom for all body techniques regardless of patient age or size[88]. This has been incorporated into all scanner platforms released since 2014, but there remains variability on scanners currently in use that were released prior to that time. CTDIvol also remains at the most appropriate method for comparing radiation exposure across different CT protocols, scanners and vendors.

The standard effective dose for a patient is calculated[89] by multiplying the DLP value by a conversion coefficient factor for the scanned body part and is measures in the millisievert (mSv). It is generally acknowledged that radiation dose is more concerning for a pediatric than an adult patient due to a relative increase in radiation sensitivity and a longer life span during which an adverse effect may manifest clinically. While precise measurements of patient-specific ED are impractical for clinical use, multiple methods of estimating ED in children have been published.[90] Many authors choose to calculate ED from the dose-length product (DLP), using published age-based conversion factors. Conversion factors published by Deak et al.[91] and Shrimpton et al.[92] are the most commonly used.[90] Alessio and Philips[93] created an online dose calculator[94] utilizing routine scanner output variables, yielding slightly higher ED estimates than the published conversion factors.[90] Although these methods are relatively straightforward, their precision is limited by the fact that they are based on patient age rather than size. Other, more detailed, methods for estimating ED have been published as well, but require specialized software.[95,96]

In 2011, the American Association of Physicists in Medicine (AAPM) task group 204 published a report proposing a new measure—termed size-specific dose estimates (SSDE)—for organ dose estimation in pediatric patients based on patient size.[97] In this method, dimensions of the patient's torso are used to reference conversion factors, which are listed on tables within the AAPM report. The SSDE is then calculated by multiplying the $CTDI_{vol}$ by the conversion factor. The effect is thought to be a more precise estimation of individual organ dose based on the patient's size rather than age. However, while SSDE shows promise for estimating organ dose, reference values have not been established for cardiac CT, and it is not currently possible to convert SSDE organ estimate to a patient dose estimate.

CTDI vol, scan DLP and total DLP are shown on the console at scan conclusion. Any comparisons between scanners and sequences should consider the phantom size used to estimate DLP and CTDIvol and the chest conversion factor used. There is no consensus on how to report CT dose in pediatric patients and we recommend listing the CTDIvol, DLP and phantom size (Table 18).

**Table 18**
Dose reduction techniques for CT in congenital heart disease.

- Perform a clinically indicated CT scan only when it will provide unique diagnostic information, or the overall patient risk is less than other imaging modalities (vascular access, contrast exposure, anesthesia and sedation, radiation exposure)
- Center the patient within the gantry
- Adjust contrast injection and image acquisition so that one scan can obtain all information needed whenever possible (no "routine" delayed venous scan)
- Limit the scan range to the area of interest (decrease z-axis coverage)
- Adjust scanner output for patient size
  - 70 or 80 kVp for most children and adolescents
  - 90 or 100 kVp for larger adolescents
- Use automated exposure algorithms for tube current and kV adjustment (if available). If the automated settings are higher than needed based on imaging experience, manually decrease the output further from what is suggested. If automated kV selection is not available, most pediatric patients and small adults may be scanned using a tube power of 70–80 kV.
- Use the highest pitch scan mode or a volumetric scan mode to minimize both image acquisition time and radiation dose
- Prospectively reduce scanner output by at least 30% if iterative reconstruction is available and if satisfied that other image quality parameters are not detrimentally affected
- Use thicker collimation if fine detail is not needed
- Use automated tube current or organ-based current reduction to protect breast tissue.
- Use prospective ECG triggering when possible for ECG gated scans
- Consider scanning without ECG gating when coronary and intracardiac anatomy is not necessary (older generation scanners where an equivalently low dose ECG-gated scan mode is not available)
- Use the minimal acquisition window necessary for coronary imaging based on heart rate
- For coronary artery imaging, consider heart rate lowering medications and coronary vasodilators the allow prospective ECG triggered techniques to be used

| Authors' reported industry/Other relationships | | | |
|---|---|---|---|
| Last name | First name | MI role | Reported industry/Other relationships |
| Abbara | Suhny | Writing group | Siemens (Institutional support), Philips (Institutional support), NIH. Textbook royalties: Elsevier/Amirysis |
| Rigsby | Cynthia K. | Writing group | Nothing to disclose |
| Crean | Andrew M. | Writing group | Nothing to disclose |
| Ghoshhajra | Brian | Writing group | Consultant: Siemens Healthcare, USA |
| Han | B. Kelly | Writing group | Grant/Research: Siemens Healthcare (Institutional support) |
| Hlavacek | Anthony | Writing group | Grant/Research: Siemens Healthcare (Institutional support) |
| Bardo | Dianna | Writing group | Consultant: Koninkljke Philips NV; Speakers Bureau: Koninkljke Philips NV |
| Lesser | John R. | Writing group | Nothing to disclose |
| Nicol | Edward D. | Writing group | Nothing to disclose |
| Raman | Subha V. | Writing group | Nothing to disclose |
| Leipsic | Jonathon | Writing group | Grant/Research: Heartflow, Edwards Lifesciences e Core lab services; Consultant: Circle CVI, Heartflow, Edwards, GE Healthcare |
| Siegel | Marilyn J. | Writing group | Consultant: Spouse GE Healthcare Consultant Advisory Board |

## References


1. Society of Cardiovascular Computed Tomography (SCCT). *Computed Tomography Imaging in Patients with Congenital Heart Disease, Part I: Rationale and Utility. An Expert Consensus Document of the Society of Cardiovascular Computed Tomography (SCCT)*. 2015 [official reference needed here].
2. Warnes CA, Williams RG, Bashore TM, et al. ACC/AHA 2008 guidelines for the management of adults with congenital heart disease: a report of the American College of Cardiology/American Heart Association Task Force on Practice Guidelines (Writing Committee to Develop Guidelines on the Management of Adults With Congenital Heart Disease). Developed in Collaboration With the American Society of Echocardiography, Heart Rhythm Society, International Society for Adult Congenital Heart Disease, Society for Cardiovascular Angiography and Interventions, and Society of Thoracic Surgeons. *J Am Coll Cardiol*. 2008;52:e143–263.
3. Khairy P, Van Hare GF, Balaji S, et al. PACES/HRS Expert Consensus Statement on the Recognition and Management of Arrhythmias in Adult Congenital Heart Disease: Executive Summary. *Heart Rhythm*. 2014;11:e81–e101.
4. Bhatt AB, Foster E, Kuehl K, et al. Congenital heart disease in the older adult: a scientific statement from the american heart association. *Circulation*. 2015;131:1884–1931.
5. Dillman JR, Hernandez RJ. Role of CT in the evaluation of congenital cardiovascular disease in children. *AJR Am J Roentgenol*. 2009;192:1219–1231.
6. Siegel MJ. Cardiac CTA: congenital heart disease. *Pediatr Radiol*. 2008;38(suppl 2):S200–S204.
7. Achenbach S, Barkhausen J, Beer M, et al. Consensus recommendations of the German Radiology Society (DRG), the German Cardiac Society (DGK) and the German Society for Pediatric Cardiology (DGPK) on the use of cardiac imaging with computed tomography and magnetic resonance imaging. *Rofo*. 2012;184:345–368.
8. Nicol ED, Gatzoulis M, Padley SP, Rubens M. Assessment of adult congenital heart disease with multi-detector computed tomography: beyond coronary lumenography. *Clin Radiol*. 2007;62:518–527.
9. Han BK, Lindberg J, Grant K, Schwartz RS, Lesser JR. Accuracy and safety of high pitch computed tomography imaging in young children with complex congenital heart disease. *Am J Cardiol*. 2011;107:1541–1546.
10. Huang MP, Liang CH, Zhao ZJ, et al. Evaluation of image quality and radiation dose at prospective ECG-triggered axial 256-slice multi-detector CT in infants with congenital heart disease. *Pediatr Radiol*. 2011;41:858–866.
11. Ben Saad M, Rohnean A, Sigal-Cinqualbre A, Adler G, Paul JF. Evaluation of image quality and radiation dose of thoracic and coronary dual-source CT in 110 infants with congenital heart disease. *Pediatr Radiol*. 2009;39:668–676.

12. Al-Mousily F, Shifrin RY, Fricker FJ, Feranec N, Quinn NS, Chandran A. Use of 320-detector computed tomographic angiography for infants and young children with congenital heart disease. *Pediatr Cardiol*. 2011;32:426–432.
13. Han BK, Overman DM, Grant K, et al. Non-sedated, free breathing cardiac CT for evaluation of complex congenital heart disease in neonates. *J Cardiovasc Comput Tomogr*. 2013;7:354–360.
14. Lell MM, May M, Deak P, et al. High-pitch spiral computed tomography: effect on image quality and radiation dose in pediatric chest computed tomography. *Invest Radiol*. 2011;46:116–123.
15. Crean A. Cardiovascular MR and CT in congenital heart disease. *Heart*. 2007;93:1637–1647.
16. Jadhav SP, Golriz F, Atweh LA, Zhang W, Krishnamurthy R. CT angiography of neonates and infants: comparison of radiation dose and image quality of target mode prospectively ECG-gated 320-MDCT and ungated helical 64-MDCT. *AJR Am J Roentgenol*. 2015;204:W184–W191.
17. Vastel-Amzallag C, Le Bret E, Paul JF, et al. Diagnostic accuracy of dual-source multislice computed tomographic analysis for the preoperative detection of coronary artery anomalies in 100 patients with tetralogy of Fallot. *J Thorac Cardiovasc Surg*. 2011;142:120–126.
18. Davenport MS, Wang CL, Bashir MR, Neville AM, Paulson EK. Rate of contrast material extravasations and allergic-like reactions: effect of extrinsic warming of low-osmolality iodinated CT contrast material to 37 degrees C. *Radiology*. 2012;262:475–484.
19. Amaral JG, Traubici J, BenDavid G, Reintamm G, Daneman A. Safety of power injector use in children as measured by incidence of extravasation. *AJR Am J Roentgenol*. 2006;187:580–583.
20. Rigsby CK, Gasber E, Seshadri R, Sullivan C, Wyers M, Ben-Ami T. Safety and efficacy of pressure-limited power injection of iodinated contrast medium through central lines in children. *AJR Am J Roentgenol*. 2007;188:726–732.
21. Plumb AA, Murphy G. The use of central venous catheters for intravenous contrast injection for CT examinations. *Br J Radiol*. 2011;84:197–203.
22. Mahabadi AA, Achenbach S, Burgstahler C, et al. Safety, efficacy, and indications of beta-adrenergic receptor blockade to reduce heart rate prior to coronary CT angiography. *Radiology*. 2010;257:614–623.
23. Dewey M, Vavere AL, Arbab-Zadeh A, et al. Patient characteristics as predictors of image quality and diagnostic accuracy of MDCT compared with conventional coronary angiography for detecting coronary artery stenoses: CORE-64 Multicenter International Trial. *AJR Am J Roentgenol*. 2010;194:93–102.
24. Roberts WT, Wright AR, Timmis JB, Timmis AD. Safety and efficacy of a rate control protocol for cardiac CT. *Br J Radiol*. 2009;82:267–271.
25. Hausleiter J, Meyer T, Hermann F, et al. Estimated radiation dose associated with cardiac CT angiography. *JAMA*. 2009;301:500–507.
26. Goldstein JA, Chinnaiyan KM, Abidov A, et al. The CT-STAT (Coronary Computed Tomographic Angiography for Systematic Triage of Acute Chest Pain Patients to Treatment) trial. *J Am Coll Cardiol*. 2011;58:1414–1422.
27. Han BK, Lindberg J, Overman D, Schwartz RS, Grant K, Lesser JR. Safety and accuracy of dual-source coronary computed tomography angiography in the pediatric population. *J Cardiovasc Comput Tomogr*. 2012;6:252–259.
28. Rigsby CK, deFreitas RA, Nicholas AC, et al. Safety and efficacy of a drug regimen to control heart rate during 64-slice ECG-gated coronary CTA in children. *Pediatr Radiol*. 2010;40:1880–1889.
29. Taylor AJ, Cerqueira M, Hodgson JM, et al. ACCF/SCCT/ACR/AHA/ASE/ASNC/NASCI/SCAI/SCMR 2010 Appropriate Use Criteria for Cardiac Computed Tomography. A Report of the American College of Cardiology Foundation Appropriate Use Criteria Task Force, the Society of Cardiovascular Computed Tomography, the American College of Radiology, the American Heart Association, the American Society of Echocardiography, the American Society of Nuclear Cardiology, the North American Society for Cardiovascular Imaging, the Society for Cardiovascular Angiography and Interventions, and the Society for Cardiovascular Magnetic Resonance. *J Cardiovasc Comput Tomogr*. 2010;4:e1–33.
30. Decramer I, Vanhoenacker PK, Sarno G, et al. Effects of sublingual nitroglycerin on coronary lumen diameter and number of visualized septal branches on 64-MDCT angiography. *AJR Am J Roentgenol*. 2008;190:219–225.
31. Lesser JR, Flygenring BJ, Knickelbine T, Longe T, Schwartz RS. Practical approaches to overcoming artifacts in coronary CT angiography. *J Cardiovasc Comput Tomogr*. 2009;3:4–15.
32. Hussein AA, Abutaleb A, Jeudy J, et al. Safety of computed tomography in patients with cardiac rhythm management devices: assessment of the U.S. Food and Drug Administration advisory in clinical practice. *J Am Coll Cardiol*. 2014;63:1769–1775.
33. Pache G, Grohmann J, Bulla S, et al. Prospective electrocardiography-triggered CT angiography of the great thoracic vessels in infants and toddlers with congenital heart disease: feasibility and image quality. *Eur J Radiol*. 2011;80:e440–e445.
34. Li J, Udayasankar UK, Toth TL, Seamans J, Small WC, Kalra MK. Automatic patient centering for MDCT: effect on radiation dose. *AJR Am J Roentgenol*. 2007;188:547–552.
35. Kuo F, Plaza M, Saigal G. Inappropriate arm positioning during scout image acquisition resulting in increased radiation dose while performing a chest CT. *Pediatr Radiol*. 2012;42:508–509.
36. Halliburton S, Arbab-Zadeh A, Dey D, et al. State-of-the-art in CT hardware and scan modes for cardiovascular CT. *J Cardiovasc Comput Tomogr*. 2012;6:154–163.
37. Shuman WP, Leipsic JA, Busey JM, et al. Prospectively ECG gated CT pulmonary angiography versus helical ungated CT pulmonary angiography: impact on cardiac related motion artifacts and patient radiation dose. *Eur J Radiol*. 2012;81:2444–2449.
38. Karlo C, Leschka S, Goetti RP, et al. High-pitch dual-source CT angiography of the aortic valve-aortic root complex without ECG-synchronization. *Eur Radiol*. 2011;21:205–212.
39. Halliburton SS, Abbara S, Chen MY, et al. SCCT guidelines on radiation dose and dose-optimization strategies in cardiovascular CT. *J Cardiovasc Comput Tomogr*. 2011;5:198–224.
40. Duan Y, Wang X, Cheng Z, Wu D, Wu L. Application of prospective ECG-triggered dual-source CT coronary angiography for infants and children with coronary artery aneurysms due to Kawasaki disease. *Br J Radiol*. 2012;85:e1190–e1197.
41. Paul JF, Rohnean A, Elfassy E, Sigal-Cinqualbre A. Radiation dose for thoracic and coronary step-and-shoot CT using a 128-slice dual-source machine in infants and small children with congenital heart disease. *Pediatr Radiol*. 2011;41:244–249.
42. Lyons KMP, Jadhav S, Bisset G, Krishnamurthy R. Dynamic Volume CTA of the Airway and Vasculature in Children: Technical Report. In: *58th Annual Meeting and Post-Graduate Course, Society of Pediatric Radiology. Bellevue, WA*. May 2015.
43. Leipsic J, LaBounty TM, Ajlan AM, et al. A prospective randomized trial comparing image quality, study interpretability, and radiation dose of narrow acquisition window with widened acquisition window protocols in prospectively ECG-triggered coronary computed tomography angiography. *J Cardiovasc Comput Tomogr*. 2013;7:18–24.
44. Margossian R, Schwartz ML, Prakash A, et al. Comparison of echocardiographic and cardiac magnetic resonance imaging measurements of functional single ventricular volumes, mass, and ejection fraction (from the Pediatric Heart Network Fontan Cross-Sectional Study). *Am J Cardiol*. 2009;104:419–428.
45. Valente AM, Cook S, Festa P, et al. Multimodality imaging guidelines for patients with repaired tetralogy of fallot: a report from the american society of echocardiography: developed in collaboration with the society for cardiovascular magnetic resonance and the society for pediatric radiology. *J Am Soc Echocardiogr*. 2014;27:111–141.
46. Burchill LJ, Mertens L, Broberg CS. Imaging for the assessment of heart failure in congenital heart disease: ventricular function and beyond. *Heart Fail Clin*. 2014;10:9–22.
47. Saremi F, Ho SY, Cabrera JA, Sanchez-Quintana D. Right ventricular outflow tract imaging with CT and MRI: Part 2, Function. *AJR Am J Roentgenol*. 2013;200:W51–W61.
48. Takx RA, Moscariello A, Schoepf UJ, et al. Quantification of left and right ventricular function and myocardial mass: comparison of low-radiation dose 2nd generation dual-source CT and cardiac MRI. *Eur J Radiol*. 2012;81:e598–604.
49. Gaudet S, Branton D, Lue RA. Characterization of PDZ-binding kinase, a mitotic kinase. *Proc Natl Acad Sci U S A*. 2000;97:5167–5172.
50. Gaudet G, Cheng KJ. Use of glucose and cellobiose by 3 strains of Fibrobacter succinogenes. *Reprod Nutr Dev*. 1990;(suppl 2):201s–202s.
51. Rizvi A, Deano RC, Bachman DP, Xiong G, Min JK, Truong QA. Analysis of ventricular function by CT. *J Cardiovasc Comput Tomogr*. 2014;9:1–12.
52. Sharma A, Einstein AJ, Vallakati A, Arbab-Zadeh A, Mukherjee D, Lichstein E. Meta-analysis of global left ventricular function comparing multidetector computed tomography with cardiac magnetic resonance imaging. *Am J Cardiol*. 2014;113:731–738.
53. Raman SV, Shah M, McCarthy B, Garcia A, Ferketich AK. Multi-detector row cardiac computed tomography accurately quantifies right and left ventricular size and function compared with cardiac magnetic resonance. *Am Heart J*. 2006;151:736–744.
54. van der Vleuten PA, de Jonge GJ, Lubbers DD, et al. Evaluation of global left ventricular function assessment by dual-source computed tomography compared with MRI. *Eur Radiol*. 2009;19:271–277.
55. Brodoefel H, Kramer U, Reimann A, et al. Dual-source CT with improved temporal resolution in assessment of left ventricular function: a pilot study. *AJR Am J Roentgenol*. 2007;189:1064–1070.
56. Asferg C, Usinger L, Kristensen TS, Abdulla J. Accuracy of multi-slice computed tomography for measurement of left ventricular ejection fraction compared with cardiac magnetic resonance imaging and two-dimensional transthoracic echocardiography: a systematic review and meta-analysis. *Eur J Radiol*. 2012;81:e757–e762.
57. Raman SV, Cook SC, McCarthy B, Ferketich AK. Usefulness of multidetector row computed tomography to quantify right ventricular size and function in adults with either tetralogy of Fallot or transposition of the great arteries. *Am J Cardiol*. 2005;95:683–686.
58. Alkadhi H, Desbiolles L, Husmann L, et al. Aortic regurgitation: assessment with 64-section CT. *Radiology*. 2007;245:111–121.
59. Feuchtner G, Plank F, Uprimny C, Chevtchik O, Mueller S. Paravalvular prosthetic valve abscess detected with 18FDG-PET/128-slice CT image fusion. *Eur Heart J Cardiovasc Imaging*. 2012;13:276–277.
60. Chan J, Marwan M, Schepis T, Ropers D, Du L, Achenbach S. Images in cardiovascular medicine. Cardiac CT assessment of prosthetic aortic valve dysfunction secondary to acute thrombosis and response to thrombolysis. *Circulation*. 2009;120:1933–1934.
61. Ghersin E, Lessick J, Agmon Y, Engel A, Kophit A, Adler Z. Candida prosthetic valve endocarditis: the complementary role of multidetector computed tomography and transoesophageal echocardiography in preoperative evaluation. *Australas Radiol*. 2007;51(suppl):B231–B234.
62. Goldstein SA, Taylor AJ, Wang Z, Weigold WG. Prosthetic mitral valve

thrombosis: cardiac CT, 3-dimensional transesophageal echocardiogram, and pathology correlation. *J Cardiovasc Comput Tomogr*. 2010;4:221–223.
63. Habets J, Symersky P, van Herwerden LA, et al. Prosthetic heart valve assessment with multidetector-row CT: imaging characteristics of 91 valves in 83 patients. *Eur Radiol*. 2011;21:1390–1396.
64. Li X, Tang L, Zhou L, et al. Aortic valves stenosis and regurgitation: assessment with dual source computed tomography. *Int J Cardiovasc Imaging*. 2009;25:591–600.
65. Symersky P, Habets J, Westers P, de Mol BA, Prokop M, Budde RP. Prospective ECG triggering reduces prosthetic heart valve-induced artefacts compared with retrospective ECG gating on 256-slice CT. *Eur Radiol*. 2012;22:1271–1277.
66. Yamasaki Y, Nagao M, Yamamura K, et al. Quantitative assessment of right ventricular function and pulmonary regurgitation in surgically repaired tetralogy of Fallot using 256-slice CT: comparison with 3-Tesla MRI. *Eur Radiol*. 2014;24:3289–3299.
67. Osawa KMT, Morimitsu Y, Akagi T, et al. Comprehensive Assessment of Morphology and Severity of Atrial Septal Defects in Adults by Computed Tomography. *J Cardiovasc Comput Tomogr*. 2015;9(4):354–612.
68. Caudron J, Fares J, Vivier PH, Lefebvre V, Petitjean C, Dacher JN. Diagnostic accuracy and variability of three semi-quantitative methods for assessing right ventricular systolic function from cardiac MRI in patients with acquired heart disease. *Eur Radiol*. 2011;21:2111–2120.
69. Niazi I, Dhala A, Choudhuri I, Sra J, Akhtar M, Tajik AJ. Cardiac Resynchronization Therapy in Patients with Challenging Anatomy Due to Venous Anomalies or Adult Congenital Heart Disease. *Pacing Clin Electrophysiol*. 2014;37:1181–1188.
70. Park EA, Lee W, Chung SY, Yin YH, Chung JW, Park JH. Optimal scan timing and intravenous route for contrast-enhanced computed tomography in patients after Fontan operation. *J Comput Assist Tomogr*. 2010;34:75–81.
71. Sandler KL, Markham LW, Mah ML, Byrum EP, Williams JR. Optimizing CT angiography in patients with Fontan physiology: single-center experience of dual-site power injection. *Clin Radiol*. 2014;69:e562–e567.
72. Grewal J, Al Hussein M, Feldstein J, et al. Evaluation of silent thrombus after the Fontan operation. *Congenit Heart Dis*. 2013;8:40–47.
73. McNitt-Gray MF. AAPM/RSNA Physics Tutorial for Residents: Topics in CT. Radiation dose in CT. *Radiographics*. 2002;22:1541–1553.
74. Siegel MJ, Hildebolt C, Bradley D. Effects of automated kilovoltage selection technology on contrast-enhanced pediatric CT and CT angiography. *Radiology*. 2013;268:538–547.
75. Siegel MJ, Ramirez-Giraldo JC, Hildebolt C, Bradley D, Schmidt B. Automated low-kilovoltage selection in pediatric computed tomography angiography: phantom study evaluating effects on radiation dose and image quality. *Invest Radiol*. 2013;48:584–589.
76. Paul JF. Individually adapted coronary 64-slice CT angiography based on precontrast attenuation values, using different kVp and tube current settings: evaluation of image quality. *Int J Cardiovasc Imaging*. 2011;27(suppl 1):53–59.
77. Zhang LJ, Qi L, De Cecco CN, et al. High-pitch coronary CT angiography at 70 kVp with low contrast medium volume: comparison of 80 and 100 kVp high-pitch protocols. *Medicine (Baltimore)*. 2014;93:e92.
78. Lee CH, Goo JM, Ye HJ, et al. Radiation dose modulation techniques in the multidetector CT era: from basics to practice. *Radiographics*. 2008;28:1451–1459.
79. Singh S, Kalra MK, Thrall JH, Mahesh M. Automatic exposure control in CT: applications and limitations. *J Am Coll Radiol*. 2011;8:446–449.
80. AAPM. *AAPM Position Statement on the Use of Bismuth Shielding for the Purpose of Dose Reduction in CT Scanning*. 2012.
81. Goetti R, Baumuller S, Feuchtner G, et al. High-pitch dual-source CT angiography of the thoracic and abdominal aorta: is simultaneous coronary artery assessment possible? *AJR Am J Roentgenol*. 2010;194:938–944.
82. Labounty TM, Leipsic J, Min JK, et al. Effect of padding duration on radiation dose and image interpretation in prospectively ECG-triggered coronary CT angiography. *AJR Am J Roentgenol*. 2010;194:933–937.
83. Moscariello A, Takx RA, Schoepf UJ, et al. Coronary CT angiography: image quality, diagnostic accuracy, and potential for radiation dose reduction using a novel iterative image reconstruction technique-comparison with traditional filtered back projection. *Eur Radiol*. 2011;21:2130–2138.
84. Oda S, Utsunomiya D, Funama Y, et al. A hybrid iterative reconstruction algorithm that improves the image quality of low-tube-voltage coronary CT angiography. *AJR Am J Roentgenol*. 2012;198:1126–1131.
85. Patino M, Fuentes JM, Hayano K, Kambadakone AR, Uyeda JW, Sahani DV. A quantitative comparison of noise reduction across five commercial (hybrid and model-based) iterative reconstruction techniques: an anthropomorphic phantom study. *AJR Am J Roentgenol*. 2015;204:W176–W183.
86. Strauss KJ, Goske MJ, Frush DP, Butler PF, Morrison G. Image Gently Vendor Summit: working together for better estimates of pediatric radiation dose from CT. *AJR Am J Roentgenol*. 2009;192:1169–1175.
87. Strauss KJ, Goske MJ. Estimated pediatric radiation dose during CT. *Pediatr Radiol*. 2011;41(suppl 2):472–482.
88. IEC 60601-2-44 Edition 3.1 2012-09, Medical electrical equipment – part 2-44: particular requirements for the basic safety and essential performance of X-ray equipment for computed tomography. *Radiology*, Accessed 10.24.14.
89. The 2007 Recommendations of the International Commission on Radiological Protection. ICRP publication 103. *Ann ICRP*. 2007;37:1–332.
90. Newman B, Ganguly A, Kim JE, Robinson T. Comparison of different methods of calculating CT radiation effective dose in children. *AJR Am J Roentgenol*. 2012;199:W232–W239.
91. Deak PD, Smal Y, Kalender WA. Multisection CT protocols: sex- and age-specific conversion factors used to determine effective dose from dose-length product. *Radiology*. 2010;257:158–166.
92. Shrimpton PC, Hillier MC, Lewis MA, Dunn M. National survey of doses from CT in the UK: 2003. *Br J Radiol*. 2006;79:968–980.
93. Alessio AM, Phillips GS. A pediatric CT dose and risk estimator. *Pediatr Radiol*. 2010;40:1816–1821.
94. Alessio A. *UW CT Effective Dose and Risk Estimator*. http://faculty.washington.edu/aalessio/doserisk2/. Published 2008 Accessed 05.20.15.
95. Huda W, Ogden KM. Computing effective doses to pediatric patients undergoing body CT examinations. *Pediatr Radiol*. 2008;38:415–423.
96. Khursheed A, Hillier MC, Shrimpton PC, Wall BF. Influence of patient age on normalized effective doses calculated for CT examinations. *Br J Radiol*. 2002;75:819–830.
97. AAPM Task Group 204 of Computer Tomography Subcommittee. *Size-specific Dose Estimates (SSDE) in Pediatric and Adult Body CT Examinations*. 2011. ISBN 9781936366088.