

SPR 2012 Annual Meeting – Nuclear Medicine Session

Marguerite T. Parisi, MD, MEd and Stephanie E. Spottswood, MD, MSPH, Moderators

Dose Reduction Strategies in Pediatric Nuclear Medicine: An Update

S. Ted Treves, MD

What activities should be considered towards dose reduction in Pediatric Nuclear Medicine?

- A. Education
- B. Appropriateness of Indications
- C. Optimization of acquisition and display protocols
- D. Application of Advanced Image Processing
- E. All of the above

Answer: E

RATIONALE

The answers A, B, C, and D are correct as they all can contribute in different ways to radiation dose reduction in pediatric nuclear medicine patients

REFERENCES

1. Gelfand MJ, Parisi MT, Treves ST. Pediatric Radiopharmaceutical Administered Doses: 2010 North American Consensus Guidelines. J Nucl Med 2011; 52(2):318-322.
2. Treves ST, Baker A, Fahey FH, Cao X, Davis RT, Drubach LA, Grant FD, Zukotynski K. Nuclear Medicine in the First Year of Life. J Nucl Med 2011; 52(6):905-925.
3. Treves ST, Parisi MT, Gelfand MJ. Pediatric Radiopharmaceutical Doses: New Guidelines. Radiol 2011; 261(2): 347-9.

FDG PET/CT of Infection: Potential Pitfall or Key Diagnostic Tool in Children with Malignancies

Marguerite T. Parisi, MD, MEd

Which of the following statements is TRUE regarding the role of Fluorine-18 FDG PET or PET//CT in pediatric infection and inflammatory imaging?

- A. The mechanism of action of F-18 FDG-PET in imaging of infection is different from that of F-18 FDG PET in imaging of malignancy.
- B. F-18 FDG PET or PET/CT can reliably distinguish infectious from non-infectious inflammation or malignancy.
- C. F-18 FDG PET/CT should replace the Tc-99m bone scan as the first line imaging procedure for diagnosing acute uncomplicated osteomyelitis.
- D. F-18 FDG PET or PET/CT is becoming increasingly important in the evaluation of children with fever of unknown origin.

Answer: D

References:

1. Basu S, Chryssikos BA, Moghadam-Kia S, Zhuang H, Torigian DA, Alavi A. Positron emission tomography as a diagnostic tool in infection: present role and future possibilities. *Semin Nucl Med* 2009; 39:36-51.
2. Parisi MT. Functional imaging of infection: conventional nuclear medicine agents and the expanding role of 18-F FDG PET. *Pediatr Radiol* 2011; 41:803-810.
3. Jasper N, Dabritz J, Frosch M, et al. Diagnostic value of [¹⁸F]-FDG PET/CT in children with unknown origin or unexplained signs of inflammation. *Eur J Nucl Med Mol Imaging* 2010; 37: 136-145.

FDG/PET in Therapeutic Response Monitoring of Lymphoma: Outcomes Predictors

M. Beth McCarville, MD

After chemotherapy treatment for Hodgkin lymphoma all of the following can cause a false positive on FDG PET-CT except which one?

- A. Histoplasmosis
- B. Non-viable tumor
- C. Xanthomatous pseudotumor
- D. Rebound thymic hyperplasia
- E. Granulocyte colony stimulating factor

Answer: B

Non-viable tumor is not FDG avid. According to the International Harmonization Criteria residual masses showing unequivocal FDG avidity should be considered to represent viable residual tumor. The significance of minimal residual FDG avidity in children with Hodgkin lymphoma is currently under investigation.

References:

1. Role of Functional Imaging in the Management of Lymphoma. Cheson B. *J Clin Oncol* 29:1844-1854
2. Expert Opinions on Positron Emission Tomography and Computed
3. Tomography Imaging in Lymphoma. Delbeke D, Stroobants S, Kerviler E, Gisselbrecht C, Meignan M, Conti P. *The Oncologist* 2009;14(suppl 2):30-40
4. The International Harmonization Project for Response Criteria in Lymphoma Clinical Trials. Bruce D. Cheson. *Hematol Oncol Clin N Am* 21 (2007) 841-854 *Hem Hematol Oncol Clin N Am* 21 (2007) 841-854 *tol Oncol Clin N Am* 21 (2007) 841-854

Rationale:

Answer a. Histoplasmosis can cause FDG avid mediastinal and hilar adenopathy and can mimic lymphoma.

- 1) Kaste SC, Howard S, McCarville MB, Krasin MJ, Hudson MM. Not all ¹⁸FDG-avid sites represent active disease in pediatric Hodgkin's. *Pediatr Radiol* 35:141-154, 2005.

Answer c. Xanthomatous pseudotumor is a histio-cyte rich pseudotumor that results from a florid response to chemotherapy-induced tumor necrosis. It has been reported in patients following treatment for lymphoma and breast cancer. It can be FDG avid and can mimic residual tumor.

1) Postchemotherapy Histiocyte-Rich Pseudotumor Involving the Spleen. Chandra P, Wen YH, Tuli S, Raphael BG, Amorosi EL, Medeiros J, Ibrahim S. *Am J Clin Pathol* 2009;132:342-348

2) Histiocyte-rich Xanthomatous Pseudotumor Mimicking Relapse on Positron Emission Tomography Imaging in an Adolescent With Primary Mediastinal Diffuse Large B-cell Lymphoma. Otto M, Shulkin B, Mondira K, Sandlund J, Snyder S, Metzger M. *Pediatr Hematol Oncol*. 2011 Nov 11. [Epub ahead of print]

3) Xanthomatous pseudotumor. An unusual postchemotherapy phenomenon in breast cancer. Tan KB, Thamboo TP, Raju GC. *Arch Pathol Lab Med*. 2003 Jun;127(6):739-41

Answer d. Rebound thymic hyperplasia occurs in 10-25% of patients receiving chemotherapy, usually within two years after initiation of therapy. On imaging the thymus is diffusely enlarged, has smooth contours and a homogenous appearance on pre and post-contrast-enhanced CT and MRI. On PET-CT the hyperplastic thymus can be FDG avid.

1) Clinical and Radiologic Review of the Normal and Abnormal Thymus: Pearls and Pitfalls. Nasseri F, Eftekhari F. *Radiographics*. 2010 Mar;30(2):413-28.

Answer e. In patients being treated for cancer, granulocyte colony stimulating factor (GCSF) can have a variable effect depending on the degree of chemotherapy induced myelosuppression. Patients receiving intensive high-dose chemotherapy will have greater myelosuppression than those receiving conventional chemotherapy. The effect of GCSF will be more evident in patients whose bone marrow is less suppressed compared to those with greater underlying suppression. GCSF can cause diffuse, generally bilaterally symmetric, increased FDG marrow avidity and homogenous splenic avidity. To avoid the effect of GCSF on PET imaging the ideal time to perform PET-CT is 2 to 4 weeks after its administration.

1) Fluorodeoxyglucose uptake in the bone marrow after granulocyte colony-stimulating factor administration in patients with non-Hodgkin's lymphoma. Hanaoka K, Hosonob M, Usamib K, Tatsumic Y, Yamazoeb Y, Komeyab Y, Tsuchiyab N, Ishiia K, Sumitaa M. *Nuclear Medicine Communications* 2011, 32:678-683

2) Effect of colony-stimulating factor and conventional or high-dose chemotherapy on FDG uptake in bone marrow. Kazama T, Swanston N, Podoloff D, Macapinlac H. *European Journal of Nuclear Medicine and Molecular Imaging* Vol. 32, No. 12, December 2005

Neuroblastoma: Respective Roles of MIBG and FDG PET/CT in Therapeutic Response Monitoring

Susan E. Sharp, MD

Which of the following statements regarding ¹²³I-MIBG is true?

- A. Less specific for neuroblastoma than FDG PET/CT
- B. Gives higher effective radiation dose than FDG PET/CT
- C. Preferred over ¹³¹I-MIBG for imaging
- D. Acts as a glucose analog
- E. None of the above

Answer: C

Rationale:

MIBG has a specificity of almost 100% for neuroblastoma. FDG is less specific, showing uptake in sites of infection/inflammation, as well as most tumors. ¹²³I-MIBG gives a lower effective radiation dose than FDG PET/CT. ¹²³I-MIBG is preferred over ¹³¹I-MIBG for imaging for several reasons; it lacks a beta particle, has an ideal photon energy for gamma camera imaging, and has a shorter half life. MIBG is related to norepinephrine and utilizes the type I catecholamine reuptake system for uptake into cells. FDG is a glucose analog.

References:

1. Shulkin BL. Neuroblastoma. In: Charron M, editor. Pediatric PET Imaging. New York: Springer; 2006. p 243-255.
2. Gelfand MJ. J Nucl Med. 1996;37:35.
3. Gelfand MJ. Pediatr Radiol. 2009;39 Suppl 1:S46-56.
4. Stabin MG, Gelfand MJ. Q J Nucl Med. 1998;42(2):93-112.

FDG PET/CT in Diagnosis and Follow-up of LCH and Wilm's Tumors: Comparison with Conventional Imaging

Michael J. Gelfand, MD

When choosing between FDG PET/CT and conventional bone imaging (bone scintigraphy and bone radiographs) for imaging of lesions of Langerhans cell histiocytosis (LCH), which of the following are true?

- A. The effective dose from FDG PET/CT is lower than the effective dose from conventional bone imaging.
- B. With successful treatment of LCH lesions, bone scintigraphy abnormalities resolve more rapidly than FDG abnormalities.
- C. With successful treatment of LCH lesions, bone radiographic abnormalities resolve more rapidly than FDG abnormalities.
- D. Disappearance of FDG uptake is believed to track resolution of the abnormal proliferative process within the lesion.
- E. Disappearance of FDG uptake occurs when bone healing is complete.

Answer: D

REFERENCES:

1. Kaste SC, Rodriguez-Galindo C, McCarville ME, Shulkin BL. PET-CT in pediatric Langerhans cell histiocytosis. *Pediatr Radiol*. 2007 Jul;37(7):615-22. Epub 2007 May 22.
2. Phillips M, Allen C, Gerson P, McClain K. Comparison of FDG-PET scans to conventional radiography and bone scans in management of Langerhans cell histiocytosis. *Pediatr Blood Cancer*. 2009 Jan;52(1):97-101.
3. Gelfand M, Sharp S, Palumbo J. Selective CT for PET/CT dose reduction in Langerhans cell histiocytosis (abstract). *J Nucl Med*. 2011; 52:1401.

RATIONALE:

Option A is false. The effective dose from FDG PET/CT using typical pediatric imaging parameters and administered activities is higher than the effective dose from conventional bone imaging [3].

Options B, C and E are false. Uptake on FDG PET within the lesion resolves with appropriate treatment of the LCH abnormal proliferative process. Bone radiographic and bone scintigraphic abnormalities resolve months later when bone healing is complete [1,2]

Pediatric Bone Tumors and Soft Tissue Sarcomas: Therapeutic Response Monitoring and Outcomes

Helen R. Nadel, MD, FRCPC

Regarding PET/CT evaluation of pediatric sarcoma:

- A. Post treatment SUV max of less than 2.5 is indicative of good prognosis in all sarcoma patients
- B. SUV 2/SUV 1 less than or equal to 0.5 may be indicative of good response in Ewing Sarcoma tumor patients
- C. 18-F FDG is specific for response assessment in treated sarcoma patients
- D. Bone scintigraphy is better for lytic metastatic disease than 18F-FDG PET/CT.
- E. All bone and soft tissue sarcoma subtypes show similar avidity on 18-F-FDG PET/CT studies

Answer: B

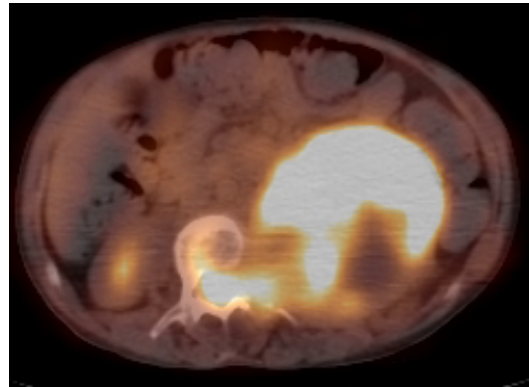
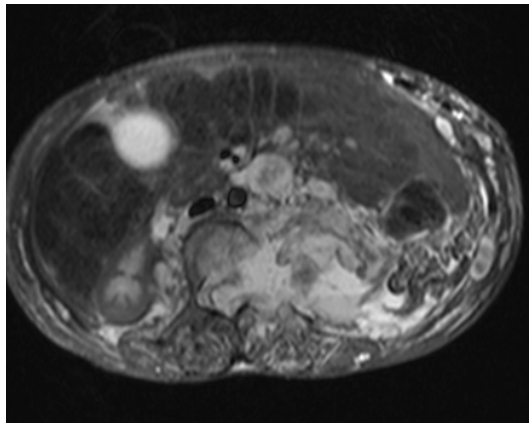
References:

1. Eary JF, O'Sullivan F, Powitan Y, Chandhury KR, Vernon C, Bruckner JD, Conrad EU. *Eur J Nucl Med Mol Imaging*. 2002 Sep;29(9):1149-54. Epub 2002 Jun 19.
2. Denecke T, Hundsdörfer P, Misch D, Steffen IG, Schönberger S, Furth C, Plotkin M, Ruf J, Hautzel H, Stöver B, Kluge R, Bierbach U, Otto S, Beck JF, Franzius C, Henze G, Amthauer H. *Eur J Nucl Med Mol Imaging*. 2010 Oct;37(10):1842-53.
3. Hawkins DS, Schuetze SM, Butrynski JE, Rajendran JG, Vernon CB, Conrad EU 3rd, Eary JF. [18F] *J Clin Oncol*. 2005 Dec 1;23(34):8828-34.
4. Gaston LL, Di Bella C, Slavin J, Hicks RJ, Choong PF. *Skeletal Radiol*. 2011 Aug;40(8):1007-15.

5. Benz MR, Czernin J, Allen-Auerbach MS, Tap WD, Dry SM, Elashoff D, Chow K, Evilevitch V, Eckardt JJ, Phelps ME, Weber WA, Eilber FC. F Clin Cancer Res. 2009 Apr 15;15(8):2856-63.
6. Israel O, Goldberg A, Nachtigal A, Militianu D, Bar-Shalom R, Keidar Z, Fogelman I. Eur J Nucl Med Mol Imaging. 2006 Nov;33(11):1280-4

Hybrid Imaging of Pediatric Brain Tumors, Neurofibromatosis and Non-Lymphomatous Head and Neck Tumors

Lisa J. States, MD



The patient shown is a teenager with NF1 and increasing back pain and lower extremity neuro-deficit. You are shown an image from an abdominal MRI and a corresponding image from a PET/CT. The SUVmax of the lesion marked by the arrow is 8.0. Which one of the following is the MOST likely etiology of the abnormality.

- A. Neuroblastoma
- B. Malignant peripheral nerve sheath tumor
- C. Osteomyelitis
- D. Benign plexiform neurofibroma

Answer: B

Rationale:

- The MRI demonstrates a large retroperitoneal tumor extending into the neural foramen with compression of the spinal cord. The axial PET/CT shows increased ¹⁸F-FDG uptake throughout most of the lesion.
- The coronal CT shows other foci of mild increased uptake including both arms and thighs.
- Other small plexiform neurofibromas seen on the MRI have no ¹⁸F-FDG uptake.
- A. Although a retroperitoneal mass in a teenager may have this appearance, NBL is not associated with NF1 and is considered less likely.
- B. Extension through the neural foramen confirms a neural origin.
- C. The imaging characteristics are not consistent with abscess or phlegmon.
- D. The high SUV favors a malignant over a benign process, however biopsy is necessary.

Reference:

Korf, B. Malignancy in Neurofibromatosis Type 1. The Oncologist 2000;5:477-485.
www.TheOncologist.com

Multi-Modality Whole Body Imaging: Data to Date and Future Perspectives

Heike E. Daldrup-Link, MD

PET/MR Design Challenges Include:

- A. PET detector must not use magnetic materials
- B. PET detector must not emit in MR frequency
- C. Eddy currents must be avoided
- D. Photon scatter due to MR materials must be minimized
- E. All of the above

Answer is E.

Rationale:

There are many challenges associated with the design of PET/MR scanners. With regard to the PET detector, these include the design of detectors free of magnetic materials, MRI-compatible PET shielding materials and detectors that do not emit in the radiofrequencies usually utilized for MRI. On the MRI side, these include avoiding or eliminating eddy currents, which could heat the PET-detector or cause noise in the PET detector, as well as photon scatter due to MRI materials.

References:

1. Daldrup-Link HE, Franzius C, Link TM, Laukamp D, Sciuk J, Jürgens H, Schober O, Rummeny EJ: Whole Body MR Imaging for Detection of Bone Metastases in children and young adults: comparison with skeletal scintigraphy and FDG PET. Am J Roentgenol 177: 229-236, 2001
2. Chavhan GB, Babyn PS. Whole-body MR imaging in children: principles, technique, current applications, and future directions. Radiographics. 2011 Oct;31(6):1757-72.
3. Kwee TC, Takahara T, Vermoolen MA, Bierings MB, Mali WP, Nievelstein RA. Whole-body diffusion-weighted imaging for staging malignant lymphoma in children. Pediatr Radiol. 2010 Oct;40(10):1592-602
4. Kleis E, Daldrup-Link HE, Matthay K, Goldsby R, Schreck C, Hawkins R, Franc B: Diagnostic value of PET/CT for the staging and restaging of pediatric tumors. Eur J Nucl Med Mol Imaging 36 (1): 23-36, 2009.
5. Fahey FH, Palmer MR, Strauss KJ, Zimmerman RE, Badawi RD, Treves ST. Dosimetry and adequacy of CT-based attenuation correction for pediatric PET: phantom study. Radiology. 2007 Apr;243(1):96-104.
6. Delso G, Fürst S, Jakoby B, Ladebeck R, Ganter C, Nekolla SG, Schwaiger M, Ziegler SI. Performance Measurements of the Siemens mMR Integrated Whole-Body PET/MR Scanner. J Nucl Med. 2011 Nov 14. [Epub ahead of print]