Introduction of the Image Gently Campaign to Pediatricians using a series of Patient Presentation Modules Entitled "Commonly Requested but Misunderstood Imaging Studies" and self assessment exam

Tiffany Lewis BA[1], Julianne Dean BA[2], Lisa Lowe MD, FAAP[3,4], Trent Phan DO[4], Cynthia Taylor MD[3,4]

[1]Kansas City University of Medicine and Biosciences, [2]Midwestern University Arizona College of Osteopathic Medicine Glendale, AZ, [3]Children's Mercy Hospitals and Clinics, [4]University of Missouri Kansas City School of Medicine, Kansas City, MO

KCUMB

UMKC UNIVERSITY OF MISSOURI KANSAS CITY

Children's Mercy HOSPITALS & CLINICS www.childrensmercy.org

Learning Objectives

After viewing this exhibit the learner should:

- **Become more familiar with the Image Gently Campaign**
- **Have increased knowledge on the indications for commonly requested but misunderstood imaging studies**
- **Be aware of a series of newsletters free to the public online**

Outline

- Educational Campaign information
- Optional links to mini-discussions for commonly ordered but misunderstood studies
- Self-assessment exam
- Conclusion
- References

Children's Mercy HOSPITALS & CLINICS
www.childrensmercy.org

Introduction

- **Recent studies suggests there has been a significant increase in the use of medical radiation, especially CT, from 2001 to 2006**
- **7 million CT studies are done per year in the pediatric population and it increases 10% per year**
- **In 2004, a survey indicated only 9% of emergency physicians and 47% radiologists were aware of radiation risks from CT**
- **Multidetector CT and 3D imaging increase radiation dose by up to 30% or 3 to 10 times**

Arch, Michael and Donald P. Frush. "Pediatric Body MDCT: A 5-year follow up survey of scanning parameters used by Pediatric Radiologists." AJR 2008; 191: 611-617.
http://www.pedrad.org/associations/5364/ig/index.cfm?page=393

Introduction

- In children, radiation induced cancer risk is increased due to younger age, lifespan, and increased sensitivity to radiation
- Our job as radiologists begins with helping clinicians determine study indications, and follows with ensuring appropriate imaging protocols
- Many practitioners are unaware of the Image Gently campaign
- A local education campaign can help get the word out about the Image Gently campaign

Purpose of Poster Presentation

- Given the increased use of medical imaging in children, especially CT, and the lack of knowledge regarding the risks to children in the general medical community, we set out to:
  - Educate practitioners on the image gently campaign
  - Educate practitioners on commonly requested but misunderstood studies
- Hopefully our educational campaign will help protect children from risk related to unnecessary radiation and sedation

Image Gently Campaign

- The Society for Pediatrics Radiology (SPR) together with the American Academy of Pediatrics (AAP) along with 33 other medical organizations have formed a multidisciplinary group, the Alliance for Radiation Safety in Pediatric Imaging
- This organization represents over 400,000 healthcare professionals promoting appropriate and high quality CT for children

American Academy of Pediatrics
DEDICATED TO THE HEALTH OF ALL CHILDREN™

Children's Mercy
HOSPITALS & CLINICS
www.childrensmercy.org

Image Gently Campaign

- 4 simple guid
  - Reduce o ion utilized
  - Scan only
  - Scan only
  - Scan once ot necessary in children
- You can take
  - http://ww

Let's increase the number pledged today!

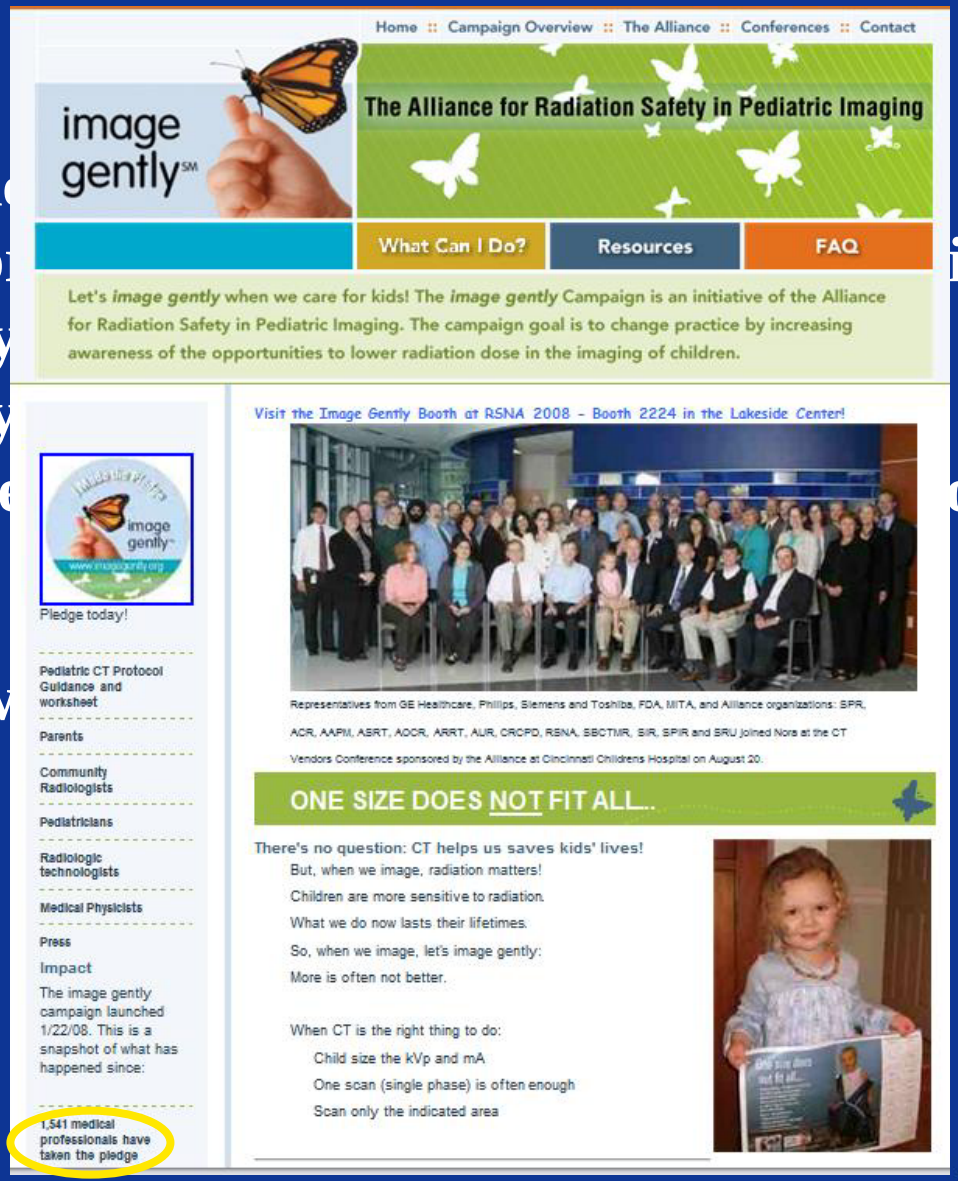

Children's Mercy HOSPITALS & CLINICS
www.childrensmercy.org



Image Gently Pledge

Yes, I want to *image gently*.

Recognizing that every member of the imaging team plays a vital role in caring for the patient and wants to provide the best care, I pledge:

- to make the image gently message a priority in staff communications this year
- to review the protocol recommendations and, where necessary, implement adjustments to our processes
- to respect and listen to suggestions from every member of the imaging team on ways to ensure changes are made
- to communicate openly with parents Thank you for committing to the goal to ***image gently*** when you image children. Spread the word in your department, practice, hospital or clinic.

First Name *

Last Name *

Email *

Profession/Role *

Please make a selection

f other, please provide:

Name of primary institution/hospital *

Primary Practice Type - Please check the description that most accurately reflects the location where you primarily practice

Please make a selection

f other type, please provide:

How did you learn about the Image gently campaign?

Please make a selection(s)
AAPM
AAP
ACR

f other, please provide

Children's Mercy
HOSPITALS & CLINICS
www.childrensmercy.org

Imaging Guidelines

- **Imaging guidelines and appropriateness criteria can be found on the ACR website:**
  - **http://www.acr.org/s_acr/bin.asp?TrackID=&SID=1&DID=14800&CID=1848&VID=2&DOC=File.PDF**

Imaging Guidelines–AAP

- Imaging guid
  American Ac te at
  http://www.a cfm
- This also incl for
  parents

American Academy of Pediatrics
DEDICATED TO THE HEALTH OF ALL CHILDREN™

Home | Parenting Corner | Health Topics | Bookstore & Publications | Professional Education & Resources | Advocacy | Members | About

Radiology

- Section on Radiology
- Executive Committee Roster
- What is a Pediatric Radiologist?
- Guidelines for Referral to Pediatric Surgical Specialists

- Radiation Safety Information for Pediatricians
- Radiation Safety Information for Parents
- Policy Statements
- Resources | Events

image gently℠ — The Alliance for Radiation Safety in Pediatric Imaging

Image Gently is the educational and awareness campaign created by the Alliance for Radiation Safety in Pediatric Imaging that was formed in July 2007. It is a coalition of health care organizations dedicated to providing safe, high quality pediatric imaging nationwide. The American Academy of Pediatrics and Society for Pediatric Radiology as well as over 33 other societies are members of this coalition representing over 500,000 health care professionals in radiology, pediatrics, medical physics, and radiation safety.

12/08

Newsletter topics (mini-discussions)

- To enter mini-discussions click on topics to the right

- To skip mini-discussions and continue though the presentation, click anywhere

- Sacral Dimples
- Craniosynostosis
- Torticollis
- Macrocephaly
- Vomiting child
- Infant Hip Imaging/Limping Child

To exit the any of the mini-discussions and return to this screen, click on the underlined blue area at the bottom of the slide

To return to the start of the presentation click here.

Children's Mercy HOSPITALS & CLINICS
www.childrensmercy.org

Sample newsletters:

- Image gently campaign

Children's Mercy HOSPITALS & CLINICS
www.childrensmercy.org

COMMONLY REQUESTED BUT MISUNDERSTOOD

imaging studies

IMAGE GENTLY CAMPAIGN

Trent Phan, DO [3], Lisa Lowe, MD [2,3] and Cindy Taylor, MD,[2,3]
Department of Radiology, Children's Mercy Hospitals and Clinics
Department of Radiology, University of Missouri-Kansas City

Since ascendancy of CT scans in the 1980s, the estimated of number studies performed has increased at least 800 percent.[1] In children, the number of CT scans has increased 2.5 fold just between 1989 and 2001.[3] With the advent of multidetector CT, radiation dose has increased approximately 30 percent with 3D studies adding 3 to 10 times more radiation. Recently an article in the New England Journal of Medicine emphasized that the risk of developing radiation induced cancer in children was increased due to their younger age, longer lifespan, and increased sensitivity to radiation.[3]

The Society for Pediatrics Radiology (SPR) together with the American Academy of Pediatrics (AAP), and eleven other medical organizations have formed a multidisciplinary group, the Alliance for Radiation Safety in Pediatric Imaging. This organization represents over 400,000 health care professionals promoting appropriate and high quality CT for children.[2] As part of its education and awareness initiative, the Alliance has developed the Image Gently Campaign. The campaign emphasizes four simple guidelines when imaging children:

1. Reduce or "child-size" the amount of radiation utilized.
2. Scan only when necessary.
3. Scan only the indicated region.
4. Scan once; multiphase scanning is usually not necessary in children.

The Image Gently Campaign Web site, www.imagegently.org, provides a wealth of information regarding CT usage in children, and is available to parents, radiologists, technologists, and clinicians. Another valuable resource to help clinicians decide which imaging study is the best study for a particular child, based on patient history, can be found at American College of Radiology (ACR) Web site: www.acr.org.

Here, various radiological studies have been rated, on a scale from 1 to 10 (best), by a group of multidisciplinary subspecialists as the most appropriate for a specific clinical condition. The appropriateness criteria can be downloaded to desktop computers or PDAs for easy access and reference.

As part of the overall initiative of the Image Gently Campaign, the Pediatric Radiology department at Children's Mercy will be providing additional information through a series of articles called Commonly Requested, But Misunderstood Imaging Studies: What You Need to Know.

References

1. Goske MJ, et. al. The 'Image Gently' campaign: increasing CT radiation dose awareness through a national education and awareness program. Pediatr Radiol 2008 38:265-269.
2. The Image Gently Campaign: Working Together to Change Practice. AJR February 2007; 100:273-274.
3. Brenner DJ, Hall EJ. Computed tomography: an increasing source of radiation exposure. N Engl J Med 2007; 357:2277-2284.

Address correspondence to:
Lisa H Lowe, MD, FAAP
Professor, Academic Chair and Program Director
Department of Radiology,
University of Missouri-Kansas City
Children's Mercy Hospitals and Clinics
2401 Gillham Road
Kansas City, MO 64152
Phone: (816) 234 - 3273 or 3725 or 3270
FAX: (816) 983-6912
E-mail: lhlowe@cmh.edu

Sample newsletters:

- Imaging sacral dimples

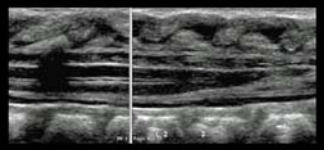

Children's Mercy HOSPITALS & CLINICS
www.childrensmercy.org

COMMONLY REQUESTED BUT MISUNDERSTOOD
imaging studies

IMAGING OF SACRAL DIMPLES

Julianne Dean BA[1], Trent Phan DO[2], Cindy Taylor MD[2,3], Lisa H Lowe MD, FAAP[2,3]
[1]Midwestern University Arizona College of Osteopathic Medicine Glendale, AZ
[2]Department of Radiology, University of Missouri-Kansas City
[3]Department of Radiology, Children's Mercy Hospitals and Clinics

When it comes to imaging, one size does not fit all. The Image Gently campaign, launched by a multi-society consortium of physicians (including the American Academy of Pediatrics and Society of Pediatric Radiology), promotes not only a reduction in radiation exposure, but also a reduction in unnecessary imaging in children. In the current and upcoming articles, we will discuss commonly ordered, but often misunderstood imaging studies.

Sacral dimples are classified as either low or high risk. Low risk lesions do not require imaging (see table), where as high risk lesions do[1]. Imaging may be accomplished with ultrasound in infants under 6 months of age and MR imaging thereafter due to the limitations of ultrasound with progressive ossification of the spine. In general, ultrasound is the screening modality of choice. Exceptions include: dimples that are draining cerebrospinal fluid (sinus tracts); or open dysraphisms, which require immediate imminent surgery and/or MR imaging[2].

Sacral Dimples

Low risk	High risk
Midline	Greater than 5 mm in diameter
Less than 5mm in diameter	Greater than 2.5 cm above anus
Located within the gluteal crease (within 2.5 cm of the anus in infants)	Located above the gluteal crease
No cutaneous abnormalities	Cutaneous abnormalities - hemangiomas, cutis aplasia, hairy patches, skin tags
No drainage	Draining cerebrospinal fluid
Can see bottom of the dimple	Bottom of dimple cannot be seen

Although Image Gently focuses mostly on the radiation risk associated with CT imaging, clinicians must recognize other imaging related risks, such as the sedation that is generally required for MR imaging in all children under 6 years of age. Timing of the imaging should be closely coordinated with the planned intervention or at least be delayed until the child is greater than 6 months of age, when there is decreased sedation risk. Finally, the judicious use of MR imaging may also help minimize the lengthy back log of patients who need MR imaging. Typically, each MR study occupies the MR scanner for about 1 hour, allowing only a few children to be imaged per day.

If you have questions or concerns regarding the imaging approach or modality to be used, help is available on line. The American College of Radiology (ACR) appropriateness criteria for nearly all imaging studies may be found on line at http://www.acr.org/SecondaryMainMenuCategories/quality_safety/app_criteria/pdf.asp . You may also contact the Department of Radiology at Children's Mercy Hospitals and Clinics at 816-234-3270.

To learn more about the Image Gently campaign and take the pledge to reduce radiation in children, please visit http://www.pedrad.org/associations/5364/ig/.

Kriss, VM, Kriss TC, Babcock, DS. The Ventriculus Terminalis of the Spinal Cord in the Neonate: A Normal Variant on Sonography. AJR 1995; 165: 1491-1493.

Lowe, LH, Johanek AJ, Moore, CW. Sonography of the Neonatal Spine: Part I, Normal Anatomy, Imaging Pitfalls, and Variations that May Simulate Disorders. AJR 2007; 188:733-738.

Address correspondence to:

Lisa H Lowe, MD, FAAP
Professor, Academic Chair and Program Director
Department of Radiology,
University of Missouri-Kansas City
Pediatric Radiology Fellowship Director,
Children's Mercy Hospitals and Clinics
2401 Gillham Road
Kansas City, MO 64152
(816) 234 - 3273 or 3725 or 3270
FAX: (816) 234 - 983-6912
E-mail: lhlowe@cmh.edu

Sample newsletters:

- Cranio-synostosis

Children's Mercy HOSPITALS & CLINICS
www.childrensmercy.org

COMMONLY REQUESTED BUT MISUNDERSTOOD
imaging studies

CRANIOSYNOSTOSIS

Julianne Dean BA[1], Trent Phan DO[2], Lisa H Lowe MD[2,3], FAAP, Cindy Taylor, MD[2,3]
[1]Department of Radiology, Children's Mercy Hospitals and Clinics
[2]Department of Radiology, University of Missouri-Kansas City
[3]Midwestern University Arizona College of Osteopathic Medicine Glendale, AZ

As mentioned in previous articles, the Imaging Gently campaign is a multisociety, multidisciplinary effort (including the American Academy of Pediatrics and Society of Pediatric Radiology) to decrease radiation risk and reduce unnecessary radiation exposure in children. In continued support of this campaign, we will discuss the imaging approach to craniosynostosis.

The incidence of sutural synostosis in the population ranges from 34 to 48 per 100,000 live births. Sagittal synostosis is the most common followed by coronal synostosis accounting for 56 percent, and 22 percent of cases, respectively.[1,2] Lambdoid sysnostosis is very rare but must be distinguished from the posterior plagiocephaly that is now frequently seen since the "Back to Sleep" campaign began in the 1990s.[3] This asymmetric flattening of the posterior calvarium is typically due to deformational forces related to sleeping position and does not usually require imaging. When imaging is required, the type of imaging depends on the history and physical examination findings, with children being classified into three categories based on low, intermediate and high risk (see table below).[3]

Risk category	Imaging approach suggested
Low risk—developmentally normal and posterior flattening only	No imaging, or 4 view skull (plain films)
Intermediate risk—children who don't clearly fit into the low or high risk group	CT Head
High risk – developmentally abnormal children and/or children with obvious head deformity almost certainly needing surgery	3D head CT

Plain films are adequate to screen for craniosynostosis in all patients, and allow for the lowest radiation dose. Plain films do not show the brain parenchyma, however, which is why cross section neuroimaging (CT or MRI) should be performed in children with possible craniosynostosis and abnormal development, to evaluate the brain as well as the head deformity.

The decision to utilize CT, and especially 3D head CT, should be made judiciously as CT radiation exposure significantly increases the lifetime cancer mortality in the pediatric population.[4] Girls are twice as sensitive as boys and infants are 15 times more sensitive than adults to the ionizing effects of radiation. Further, 3D head CT results in a 3 to 10 times increase in radiation exposure over conventional CT of the head. To put this in context, the radiation exposure to an infant from a 3D CT may be equal to 150 head CT scan's in an older adult. Therefore, 3D head CT should not be used as a screening examination, but only if surgery is planned. If surgery is needed, waiting to request a 3D CT until such time as the surgery is imminent is useful to prevent repeated examinations, which may subject the child to unnecessary radiation exposure.

If you have concerns regarding imaging approach or the modality to be used, the ACR appropriateness criteria may be found online at http://www.acr.org/SecondaryMainMenuCategories/quality_safety/app_criteria/pdf.aspx or you may contact the Department of Radiology at Children's Mercy Hospitals and Clinics.

To learn more about the Imaging Gently Campaign and take the pledge to reduce radiation in children, please visit http://www.pedrad.org/associations/5364/ig/.

[1]Cohen, MM Jr. Epidemiology of Craniosynostosis. In: Cohen, MM Jr, ed Craniosynostosis: diagnosis, evaluation, and management, 2nd ed. New York: Oxford University Press, 2000: 112-118.

[2]Lajeunie, E, Le Merrer, et al. Genetic study of nonsyndromic coronal craniosynostosis. Am J Med Genet 1995; 55: 500-504.

[3]Medina, LS, R Richardson, and K Crone. Children with Suspected Craniosynostosis: A Cost Effectiveness Analysis of Diagnostic Strategies. AJR 2002; 179: 215-221.

[4]Brenner DJ, Elliston CD, Hall EJ, Berdon WE. Estimated risks of radiation – induced fatal cancer from pediatric CT. AJR Am J Roentgenol. 2001;176:289-296.

Address correspondence to:

Lisa H Lowe, MD, FAAP
Professor, Academic Chair and Program Director
Department of Radiology,
University of Missouri-Kansas City
Pediatric Radiology Fellowship Director,
Children's Mercy Hospitals and Clinics
2401 Gillham Road
Kansas City, MO 64152
Phone: (816) 234 - 3273 or 3725 or 3270
FAX: (816) 983-6912
E-mail: lhlowe@cmh.edu

Sample newsletters:

- Imaging torticollis

Children's Mercy HOSPITALS & CLINICS
www.childrensmercy.org

COMMONLY REQUESTED BUT MISUNDERSTOOD
imaging studies

IMAGING TORTICOLLIS

Tiffany Lewis BA[1], Lisa H. Lowe MD, FAAP[2,3] and Cynthia Taylor MD[2,3]
[1]Kansas City University of Medicine and Biosciences College of Osteopathic Medicine
[2]Department of Radiology, Children's Mercy Hospitals and Clinics
[3]Department of Radiology, University of Missouri Kansas City

Reductions in unnecessary imaging, radiation exposure, and sedation in children are the focus of the *Imaging Gently Campaign*, a nationwide, multidisciplinary effort that includes organizations such as the American Academy of Pediatrics and the Society of Pediatric Radiology. In continued support of this campaign, we will discuss the *imaging approach to torticollis*.

Torticollis refers to a unilateral contraction of the sternocleidomastoid muscle that forces the patient to hold the head tilted toward the affected side with rotation of the chin toward the contralateral shoulder[1]. The differential diagnosis of torticollis varies widely and imaging may or may not be appropriate. The type of imaging used is based on age, neurological manifestations and history of trauma or infection (see table).

Clinical Presentation/ Age	Initial imaging approach
< 3 months; asymptomatic except for torticollis	Ultrasound
> 3 months; asymptomatic except for torticollis	No imaging; conservative Rx 1-2 weeks; Persistent symptoms –CT without contrast
Any age with history of trauma	CT without contrast
Any age with symptoms of infection	CT with IV contrast
Any age with neurological symptoms	MRI

In infants under 3 months of age, especially those with prior forceps delivery, fibromatosis coli (hematoma of the sternocleidomastoid muscle) is the most common cause of torticollis[1]. It typically presents with torticollis and a "lump" in the sternocleidomastoid muscle between 6-12 weeks of age. Ultrasound is the initial study of choice in these otherwise asymptomatic infants as it provides reliable, cost-effective, diagnostic information without harmful radiation or sedation[2]. Most cases of torticollis due to fibromatosis coli will spontaneously resolve, but persistent or severe cases may require physical therapy or, in rare cases, surgical release[2].

In children > 3 months of age, the most common cause of torticollis is idiopathic, self-limiting rotary subluxation. If rotatory subluxation (torticollis) persists for several weeks despite conservative management, the child is at risk for rotatory fixation. Rotatory fixation is a more serious condition that may involve bony fusion and occasionally requires surgery. Unenhanced CT is the imaging study of choice to evaluate persistent unexplained, otherwise asymptomatic torticollis[3].

At any age, to evaluate trauma, the study of choice is unenhanced CT. In children of all ages with symptoms of infection, CT with contrast is the imaging modality of choice. Torticollis at any age associated with neurological signs or symptoms raises concern for spinal cord pathology and should be evaluated with MRI.

If you have questions or concerns regarding the imaging approach or modality to be used, help is available on line. The American College of Radiology (ACR) appropriateness criteria for nearly all imaging studies may be found online at **http://www.acr.org/SecondaryMainMenuCategories/quality_safety/app_criteria/pdf.asp**. You may also contact the Department of Radiology at Children's Mercy Hospitals and Clinics at 816-234-3270.

To learn more about the Imaging Gently Campaign, and take the pledge to reduce radiation in children along with thousands of other pediatric clinicians, please visit **http://www.pedrad.org/associations/5364/ig/**.

Address correspondence to:
Lisa H Lowe, MD, FAAP
Professor, Academic Chair and Program Director
Department of Radiology,
University of Missouri-Kansas City
Children's Mercy Hospitals and Clinics
2401 Gillham Road
Kansas City, MO 64152
Phone: (816) 234 - 3273 or 3725 or 3270
FAX: (816) 983-6912
E-mail: lhlowe@cmh.edu

References:

1. Do, Twee. Congenital Muscular Torticollis: Current Concepts and Review of Treatment. Current Opinion in Pediatrics 2006; 18:26-29.
2. Dudkiewicz, I, Ganel, A, Blankstein, A. Congenital Muscular Torticollis in Infants: Ultrasound-Assisted Diagnosis and Evaluation. Journal of Pediatric Orthopaedics 2005; 25:812-814.
3. Subach, BR, McLaughlin, MR, Albright, LA, Pollack, IF. Current Management of Pediatric Atlantoaxial Rotatory Subluxation. Spine 1998; 23:2174-2179.

Sample newsletters:

- Imaging macrocephaly

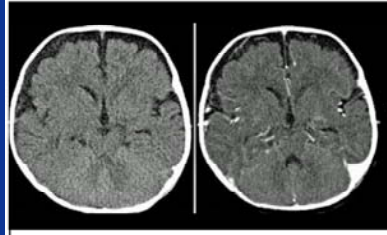

Children's Mercy HOSPITALS & CLINICS
www.childrensmercy.org

COMMONLY REQUESTED BUT MISUNDERSTOOD
imaging studies

IMAGING MACROCEPHALY

Tiffany Lewis BA[1], Lisa H. Lowe MD, FAAP[2, 3] and Cynthia Taylor, MD[2, 3]
[1]Kansas City University of Medicine and Biosciences College of Osteopathic Medicine
[2]Department of Radiology, Children's Mercy Hospitals and Clinics and the
[3]Department of Radiology, University of Missouri Kansas City

Reductions in both unnecessary imaging and radiation exposure in children are the focus of the *Imaging Gently Campaign*, a nationwide, multidisciplinary effort including organizations such as the American Academy of Pediatrics and the Society of Pediatric Radiology. In continued support of this campaign to reduce radiation and unnecessary imaging, we will discuss the imaging approach to macrocephaly.

Macrocephaly refers to a head circumference greater than two standard deviations above the mean (>95%) for age, sex, race and gestation. The differential diagnosis of macrocephaly most often includes the normal variation of benign enlarged subarachnoid spaces (BESS). Less often, it is due to a pathological state such as subdural hematoma, hydrocephalus and, extremely rarely, an intracranial mass. When imaging is considered, the type of imaging is based on the child's development and age (see table below).

Clinical Presentation & Age	Imaging approach
Developmentally normal infant/child with open fontanel	Head ultrasound
Developmentally normal infant/child with closed fontanel	CT or MRI
Developmentally abnormal infant/child with open or closed fontanel	MRI

In developmentally normal infants (normal neurological exam) with open fontanels short term clinical follow-up with serial measurements of the head circumference alone with or without head ultrasound is reliable and safe [1]. If the head circumference stabilizes, imaging is not suggested. If the head continues to enlarge disproportionately to the child's growth, ultrasound is useful to screen for severe hydrocephalus, or rarely, a mass so large it may cause macrocephaly.

In developmental normal children with a closed fontanel, ultrasound is not possible. Instead, CT or MRI of the brain are required if imaging is performed. In these cases, the utility of close follow-up with serial head circumference measurements versus risks of imaging (radiation with CT or sedation risk with MRI) must be considered on a case by case basis [2]. In certain circumstances one mode of imaging may offer an advantage over the other, such as if visualization of the bones is important, then CT is preferred [3].

In developmentally abnormal infants or children, MRI is needed to carefully evaluate the brain parenchyma, as well as the extra-axial spaces [2, 3]. Parenchymal brain signal changes of rare metabolic disorders, such as Alexander and Canavan disease, may present with macrocephaly and are best visualized with MRI.

To learn more about the Imaging Gently Campaign, and take the pledge to reduce radiation in children along with thousands of other pediatric clinicians, please visit **http://www.pedrad.org/associations/5364/ig/**.

Further information regarding the imaging approach to pediatric disorders may be found at the American College of Radiology Web site (imaging appropriateness criteria) at **http://www.acr.org/SecondaryMainMenuCategories/quality_safety/app_criteria.aspx**. You may also contact the Department of Radiology at Children's Mercy Hospitals and Clinics at 816-234-3270.

Address correspondence to:
Lisa H Lowe, MD, FAAP
Professor, Academic Chair and Program Director
Department of Radiology,
University of Missouri-Kansas City
Children's Mercy Hospitals and Clinics
2401 Gillham Road
Kansas City, MO 64152
Phone: (816) 234 - 3273 or 3725 or 3270
FAX: (816) 983-6912
E-mail: lhlowe@cmh.edu

References:

1. Smith, MR, JC Leonidas, J Maytal. The Value of Head Ultrasound in Infants with Macrocephaly. Pediatric Radiology 1998; 28:143-146.
2. Wilms G, Vanderschueren G, et al. CT and MR in infants with pericerebral collections and macrocephaly: benign enlargement of the subarachnoid spaces versus subdural collections. American Journal of Neuroradiology 1993; 14:855-860.
3. Hudgins, R, Boydston WR. All Heads Great and Small, Macrocephaly. Children's Healthcare of Atlanta. http://www.choa.org/default.aspx?id=921. Accessed June 15, 2008.

Sample newsletters:

- Imaging the vomiting infant

Children's Mercy HOSPITALS & CLINICS
www.childrensmercy.org

COMMONLY REQUESTED BUT MISUNDERSTOOD
imaging studies

IMAGING THE VOMITING INFANT

Tiffany Lewis BA[1], Steve T. Welch MD[2,3], Lisa H. Lowe MD, FAAP[2,3] and Cynthia Taylor MD[2,3]
[1]Kansas City University of Medicine and Biosciences College of Osteopathic Medicine
[2]Department of Radiology, Children's Mercy Hospitals and Clinics and the
[3]The University of Missouri-Kansas City

In continued support of the *Imaging Gently Campaign*, a nation wide, multidisciplinary effort by organizations such as the American Academy of Pediatrics and the Society of Pediatric Radiology focused on reducing unnecessary imaging, radiation exposure and sedation in children, this Children's Mercy newsletter we will discuss *imaging of the vomiting infant*.

The most common cause of infantile vomiting is gastroesophageal reflux disease (GERD). For the purpose of this discussion, we will assume the infant is a normal weight. Many healthy infants are radiated during unnecessary upper gastrointestinal imaging (UGI) in order to rule out "GERD." Since the UGI is a study of anatomy and not function, "GERD" is not typically an UGI diagnosis unless it is extremely severe. Functional studies to evaluate GERD such as pH probes and nuclear medicine often have better sensitivity and less radiation compared to an UGI. Proper imaging begins with knowing if the child's vomiting is bilious or non-bilious, when the vomiting began, if any signs of airway compression are present, and the age of the child (see table).

Clinical Presentation	Initial approach
Bilious vomiting – This is an emergency. Refer to a pediatric facility if possible	**NG tube confirmation and abdominal radiographs** • If radiographs suggest a proximal obstruction (few or no dilated bowel loops); request an UGI as malrotation with midgut volvulus is most likely • If radiographs suggest distal obstruction (many dilated bowel loops); request contrast enema • No need for small bowel follow through
Non-bilious vomiting (often since birth) + normal weight gain	**No imaging; GERD is most likely** • Treat conservatively (anti-reflux meds)
Non-bilious vomiting + airway symptoms (cough, stridor)	**Request UGI** • Vascular ring is most likely • No need for small bowel follow through
Non-bilious vomiting in a 4 to 8 week old	**Pyloric ultrasound** • Pyloric stenosis most likely • No need for UGI or small bowel follow through

Bilious vomiting in infants is an emergency and proper imaging is crucial for appropriate treatment. Insertion of an nasogastric (NG) tube is required before proceeding with any imaging studies in order to provide concrete evidence of true bilious emesis and distinguish it from infants with "bilious rumors" (those with unconfirmed histories of bilious vomiting). Besides treating the infant by decompressing the bowel, placement of an NG tube prevents exposure to unnecessary UGI radiation in infants without true bilious vomiting. If bile is confirmed in the NG aspirate, intestinal obstruction is present. Next, abdominal radiographs should be requested in order to determine if an UGI or a contrast enema is the most appropriate study (see table).

Although proximal bowel obstructions in infants may be due to a variety of processes, malrotation with midgut volvulus is the most urgent concern and is diagnosed on UGI. It is important to note that all pediatric UGI examinations include evaluation of the proximal small bowel to the level of the duodenojejunal junction and it is therefore not necessary to order a separate small bowel follow-through examination as part of the work up for malrotation with volvulus. Distal bowel obstructions, which are also due to a variety of process, are beyond the scope of this newsletter. Finally, some infants will require both an UGI and a contrast enema to evaluate for all urgent conditions.

Non-bilious vomiting, typically present since birth, is the most often due to GERD and no imaging is required.[1] Infants with suspected GERD may be diagnosed by a trial of anti-reflux medications. However, if vomiting (GERD) is severe enough to cause the infant to lose weight, a GI or surgical consultation may be useful to determine the appropriate intervention.

Non-bilious vomiting associated with airway symptoms (noisy breathing, stridor, cough) should be evaluated with an UGI to look for a vascular ring.[2]

Non-bilious vomiting in 4-8 week old infant is most often due to pyloric stenosis. Infants with pyloric stenosis often present with projectile vomiting and are easily diagnosed with pyloric ultrasound (transverse pyloric muscle measurement > 3mm).

To learn more about the Imaging Gently Campaign, and take the pledge to reduce radiation in children along with thousands of other pediatric clinicians, please visit http://www.pedrad.org/associations/5364/ig/.

Further information regarding the imaging approach to pediatric disorders may be found at the American College of Radiology Web site (imaging appropriateness criteria) at http://www.acr.org/SecondaryMainMenuCategories/quality_safety/app_criteria.aspx or contact the Department of Radiology at Children's Mercy Hospitals and Clinics at 816-234-3270.

Address correspondence to:
Lisa H Lowe, MD, FAAP
Professor, Academic Chair and Program Director
Department of Radiology,
University of Missouri-Kansas City
Children's Mercy Hospitals and Clinics
2401 Gillham Road
Kansas City, MO 64152
Phone: (816) 234 - 3273 or 3725 or 3270
FAX: (816) 983-6912
E-mail: lhlowe@cmh.edu

References:
1. Hernanz-Schulman M. Infantile Hypertrophic Pyloric Stenosis. Pediatric Radiology 2003:227(3): 319-31.
2. Turner A, Gavel G, Coutts J. "Vascular Rings – Presentation, Investigation and Outcome." European Journal of Pediatrics. 2005 May:164(5): 266-70.
3. Malcom GE, Raio CC, Del Rios M, Blaivas M, Tsung JW. "Feasibility of Emergency Physician Diagnosis of Hypertrophic Pyloric Stenosis using Point-of-Care Ultrasound: A Multi-Center Case Series." Journal of Emergency Medicine. 2008 June 20.

Sample newsletters:

- Imaging the hip

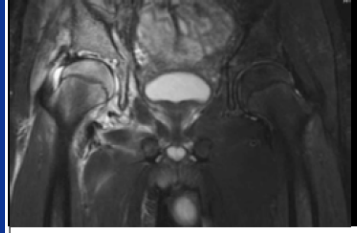

Children's Mercy HOSPITALS & CLINICS
www.childrensmercy.org

COMMONLY REQUESTED BUT MISUNDERSTOOD
imaging studies

IMAGING INFANT HIPS AND THE LIMPING CHILD

Julianne Dean BA[1], Brent Cully MD[2], Lisa H Lowe MD FAAP [2,3], and Cindy Taylor MD[2]
[1]Midwestern University, Glendale, AZ, [2]Children's Mercy Hospitals and Clinics, Kansas City, MO, and [3]The University of Missouri-Kansas City

In continued support of the *Image Gently Campaign*, the Radiology Department at Children's Mercy continues this newsletter series entitled "Commonly Requested but Misunderstood Studies" with a discussion on imaging infant hips and the limping child.

The most common reason for hip imaging in the newborn is hip dysplasia. Risk factors include being female, breech presentation, firstborn and family history of hip dysplasia (1).

Due to patient size and lack of epiphyseal ossification, ultrasound is the initial study of choice for possible hip dysplasia in children less than 6 months of age. After 6 months, radiographs of the pelvis are indicated.

In children with a limp or hip pain, the appropriate study (plain radiographs vs. ultrasound vs. MRI vs. bone scan) is strongly determined by the clinical history and physical exam. Specifically, one must know: (1) The child's age (2) If a fever is present, how high (3) If there is hip pain with manipulation (4) Does the child refused to bear weight and (5) If there are positive lab inflammatory markers (ESR, CRP) and if so, how positive? Using this information, it may be possible to distinguish viral versus bacterial joint infection versus osteomyelitis and determine the appropriate imaging.

History and physical	Probable diagnosis	Imaging Modality of choice
No signs of infection (fever, WBC, sed rate, etc.)	Transient (viral) synovitis or AVN	• NO ACUTE IMAGING NEEDED • Request radiographs if persistent
Minimal signs of infection	Transient synovitis	• NO ACUTE IMAGING NEEDED • Hip tap rarely for pain control
Many signs of infection & Severe limp or refusal to bear weight and severe pain on passive exam	Septic hip Osteomyelitis	• Refer to Emergency Department and/or Orthopaedic Surgery • Consider ultrasound to search for hip effusion
Many signs of infection & No or mild limp and mild-moderate pain on passive exam	Osteomyelitis	• MRI • Forego hip ultrasound as an effusion may be present, but may not need to be tapped

Children with transient (toxic) synovitis, are generally 3 to 8 years of age, present with a limp and less often refusal to bear weight. Symptoms usually resolve spontaneously within a few days. A low grade fever may be present or the child may be afebrile. Moderate pain is associated with passive motion of the hip on physical exam. NO IMAGING or HIP ASPIRATION is needed in children with toxic synovitis although many will have hip effusions. If symptoms persist, pelvic radiographs may be useful to evaluate for avascular necrosis.

Children with septic arthritis present at any age with a severe limp or inability to bear weight, fever, and guarding or severe pain with passive motion of the hip. In such cases, with a high suspicion of a septic joint, the child should be referred to an orthopedic surgeon, who will usually aspirate the joint. Orthopedic surgery will determine whether to obtain an ultrasound (will show an effusion) or plain radiograph prior to hip joint aspiration.

Children with osteomyelitis of the hip are the trickiest because symptoms can mimic a septic hip joint in many ways. Osteomyelitis should be suspected when a child has a fever and positive inflammatory markers typical of septic joint; however, the degree of hip pain is mild to moderate with passive motion causing the child to limp rather than refuse to bear weight. Reactive joint effusions are often present with hip osteomyelitis, thus an ultrasound may be misleading. The modality of choice to evaluate osteomyelitis is MRI (2).

If there are concerns regarding imaging approach or modality to be used, the ACR appropriateness criteria may be found on line at http://www.acr.org/SecondaryMainMenuCategories/quality_safety/app_criteria/pdf.aspxor you may contact the Department of Radiology at Children's Mercy Hospitals and Clinics.

To learn more about the Image Gently Campaign and take the pledge to reduce radiation in children, please visit http://www.pedrad.org/associations/5364/ig/.

Address correspondence to:
Lisa H Lowe, MD, FAAP
Professor, Academic Chair and Program Director
Department of Radiology,
University of Missouri-Kansas City
Children's Mercy Hospitals and Clinics
2401 Gillham Road
Kansas City, MO 64152
Phone: (816) 234 - 3273 or 3725 or 3270
FAX: (816) 983-6912
E-mail: lhlowe@cmh.edu

References

Beaty, James H. "Congenital and Developmental Anomalies of the Hip/Pelvis". Canale and Beaty: Campbell's Operative Orthopaedics, 11th Ed. 2007. Accessed www.mdconsult.com

Frick, Steven L. Evaluation of the Child who has Hip Pain. Orthopedic Clinics of North America. 2006; 37:133-140.

CMH website with downloadable newsletters

- These ne … unity practitio
- They are … l and Clinics R
  - http://v … =183
- Use of th

Children's Mercy HOSPITALS & CLINICS
www.childrensmercy.org

Find a Doctor | Press Room | Careers | Directions and Locations

Search Go

About Us | Departments | Contact Us | Ways to Give | Mobile

For Patients and Families Your Child's Health Clinical Services | For Health Care Professionals Medical Education Medical Research

Home > Departments > Radiology

- Radiology
- Diagnosis
- Services
- Contact Us
- Children's Mercy South
- Home Care
- Outpatients Clinics
- Nurse Practitioners
- Referral Notes
- **Commonly Requested, but Misunderstood Imaging Studies**
- Why Children's Mercy

Commonly Requested, but Misunderstood Imaging Studies

Print Friendly

What You Need To Know

The articles below are provided as part of the overall initiative of the Image Gently Campaign. These articles have been prepared by the Pediatric Radiology department at Children's Mercy Hospitals and Clinics to inform clinicians regarding commonly requested, but misunderstood imaging studies.

- Image Gently Campaign
- Imaging of Sacral Dimples
- Craniosynostosis
- Imaging Torticollis
- Imaging Macrocephaly
- Imaging the Vomiting Infant

Newsletters

Copyright © 2008 The Children's Mercy Hospital
Legal | Privacy and Terms of Use | Site Map

CMH Employees

Return to newsletter page or click anywhere to continue with next topic

Children's Mercy HOSPITALS & CLINICS
www.childrensmercy.org

Self-Assessment Exam

- Welcome to the self assessment exam where you can sees what you have learned
- Please answer the next 5 questions by clicking True or False
- Follow prompts on screen to obtain the correct answer and move on to the next question

Self-assessment Exam: Question #1

True or False

Boys are twice as sensitive to radiation as girls.

Return to list of minidiscussions or click anywhere to continue with next topic

Children's Mercy HOSPITALS & CLINICS www.childrensmercy.org

Radiation Sensitivity

True is not the correct answer, good try.

Move to correct answer

Return to list of minidiscussions or click anywhere to continue with next topic

Children's Mercy HOSPITALS & CLINICS
www.childrensmercy.org

Radiation Sensitivity

False, good job!

Actually girls are twice as susceptible to carcinogenesis as boys.

- **Brenner DJ, Elliston CD, Hall EJ, and WE Berdon. Estimated risks of radiation-induced fatal cancer from pediatric CT. *AJR* 2001;176: 289-296**

Click anywhere to move to next question

Return to list of minidiscussions or click anywhere to continue with next topic

Children's Mercy HOSPITALS & CLINICS www.childrensmercy.org

Self Assessment Exam: Question #2

True or False

Infants are up to 15 times more sensitive to radiation than adults.

Return to list of minidiscussions or click anywhere to continue with next topic

Children's Mercy HOSPITALS & CLINICS www.childrensmercy.org

Radiation Sensitivity

False, nice try but incorrect.

Move to correct answer

Return to list of minidiscussions or click anywhere to continue with next topic

Children's Mercy HOSPITALS & CLINICS www.childrensmercy.org

Radiation Sensitivity

True! Correct.

"Because they have more rapidly dividing cells than adults and have a longer life expectancy, the odds that children will develop cancer from x-ray radiation are higher than adults."

- **"One size does not fit all: Reducing Risks from Pediatric CT" ACR Bulletin February 2001 57(2): 20-23.**

Click anywhere to move to next question

Return to newsletter page or click anywhere to continue with next topic

Children's Mercy HOSPITALS & CLINICS www.childrensmercy.org

Self Assessment Exam: Question #3

True or False

3D CT should be utilized as a screening test for children suspected of having craniosynostosis.

Return to list of minidiscussions or click anywhere to continue with next topic

Children's Mercy HOSPITALS & CLINICS
www.childrensmercy.org

3D CT

True, nice try, but incorrect.

Move to correct answer

Return to list of minidiscussions or click anywhere to continue with next topic

Children's Mercy HOSPITALS & CLINICS www.childrensmercy.org

3D CT

False, good job!

3 dimensional CT adds 3-10 times more radiation and is mostly reserved for surgical planning.

Click anywhere to move to next question

Return to list of minidiscussions or click anywhere to continue with next topic

Children's Mercy HOSPITALS & CLINICS
www.childrensmercy.org

Self Assessment Exam: Question #4

True or False

It has been estimated that radiation from CT may cause up to 1:1,000 neoplasms.

Return to list of minidiscussions or click anywhere to continue with next topic

Children's Mercy HOSPITALS & CLINICS
www.childrensmercy.org

Cancer

False. Nice try!

Move to correct answer

Return to list of minidiscussions or click anywhere to continue with next topic

Children's Mercy HOSPITALS & CLINICS
www.childrensmercy.org

Cancer

True.

It has been estimated that CT may cause up to 1 in 1,000 neoplasms

- **Brenner, DJ Estimating cancer risks from pediatric CT: going from the qualitative to the quantitative. Pediatric Radiology 2002: 32: 228-231**

Click anywhere to move to next question

Return to list of minidiscussions or click anywhere to continue to the final question

Children's Mercy HOSPITALS & CLINICS www.childrensmercy.org

Self assessment #5

True or False

Many pediatric radiologists estimate that greater than 30 percent of CT scans are unneeded.

Return to list of minidiscussions or click anywhere to continue with next topic

Children's Mercy HOSPITALS & CLINICS
www.childrensmercy.org

Need for scans

False. Incorrect, but good try.

Move to correct answer

Return to list of minidiscussions or click anywhere to continue with next topic

Children's Mercy
HOSPITALS & CLINICS
www.childrensmercy.org

Need for scans

True. Nice job!

"A poll might show that we consider 10% to 30% of our CT examinations unnecessary. A nonscientific consensus at the ALARA conference was that about 30% of CT examinations in children were totally unnecessary or were readily replaceable by examinations not using radiation."

- **Slovis, Thomas L. Introduction to Seminar in Radiation Dose Reduction. Pediatric Radiology (2002) 32: 707-708.**

Please click anywhere for references and conclusion.

Return to list of minidiscussions page or click anywhere to continue with next topic

Children's Mercy HOSPITALS & CLINICS
www.childrensmercy.org

Conclusion

- The newsletters in this presentation are available to the public on the internet and are not copyright protected
- They were distributed to 4,500 primary care physicians, nurse practitioners, and physician assistants in MO and KS along with our medical staff

Return to the BEGINNING of presentation by clicking here

Return to list of minidiscussions by clicking here

Children's Mercy HOSPITALS & CLINICS
www.childrensmercy.org

Conclusions

- This ends the presentation on our education campaign
- If you wish to go to the list of mini-discussion topics click here
- Return to beginning of presentation by clicking here
- Click anywhere for references
- Thank you for your attention!

Children's Mercy
HOSPITALS & CLINICS
www.childrensmercy.org

References

1. Arch, Michael and Donald P. Frush. "Pediatric Body MDCT: A 5-year follow up survey of scanning parameters used by Pediatric Radiologists." AJR 2008; 191: 611-617.
2. Brenner DJ, Hall EJ. Computed tomography: an increasing source of radiation exposure. *N Engl J Med* 2007; 357:2277-2284.
3. Brenner, DJ Estimating cancer risks from pediatric CT: going from the qualitative to the quantitative. Pediatric Radiology 2002: 32: 228-231
4. Brenner DJ, Elliston CD, Hall EJ, and WE Berdon. Estimated risks of radiation-induced fatal cancer from pediatric CT. *AJR* 2001;176: 289-296
5. Cohen, MM Jr. Epidemiology of Craniosynostosis. In: Cohen, MM Jr, ed Craniosynostosis: diagnosis, evaluation, and management, 2nd ed. New York: Oxford University Press, 2000: 112-118.
6. Do, Twee. Congenital Muscular Torticollis: Current Concepts and Review of Treatment. *Current Opinion in Pediatrics* 2006; 18:26-29
7. Dudkiewicz, I, Ganel, A, Blankstein, A. Congenital Muscular Torticollis in Infants: Ultrasound-Assisted Diagnosis and Evaluation. *Journal of Pediatric Orthopaedics* 2005; 25:812-814.
8. Goske MJ, et. al. The 'Image Gently' campaign: increasing CT radiation dose awareness through a national education and awareness program. *Pediatr Radiol* 2008 38:265-269.
9. The Image Gently Campaign: Working Together to Change Practice. *AJR* February 2007; 100:273-274.
10. Kriss, VM, et. al. Occult spinal dysraphism in neonates: assessment of high risk cutaneous stigmata on sonography. AJR 17 (6): 1687-92.

References

11. Kriss, VM, Kriss TC, Babcock, DS. The Ventriculus Terminalis of the Spinal Cord in the Neonate: A Normal Variant on Sonography. AJR 1995; 165: 1491-1493.
12. Lajeunie, E, Le Merrer, et al. Genetic study of nonsyndromic coronal craniosynostosis. Am J Med Genet 1995; 55: 500-504
13. Lee, CI, Haim, AH, Monico, EP et al. Diagnostic CT scans: assessment of patient, physician, and radiologist awareness of radiation dose and possible risks. Radiology 2004; 231: 393-398.
14. Lowe, LH, Johanek AJ, Moore, CW. Sonography of the Neonatal Spine: Part I, Normal Anatomy, Imaging Pitfalls, and Variations that May Simulate Disorders. AJR 2007; 188:733-738.
15. Medina, LS, R Richardson, and K Crone. Children with Suspected Craniosynostosis: A Cost Effectiveness Analysis of Diagnostic Strategies. AJR 2002; 179: 215-221.
16. "One size does not fit all: Reducing Risks from Pediatric CT" ACR Bulletin February 2001 57(2): 20-23.
17. Slovis, Thomas L. Introduction to Seminar in Radiation Dose Reduction. Pediatric Radiology (2002) 32: 707-708
18. Smith, R, et al. The value of head ultrasound in infants with macrocephaly. Pediatric Radiology. 1998 Mar; 28(3): 143-146.
19. Subach, BR, McLaughlin, MR, Albright, LA, Pollack, IF. Current Management of Pediatric Atlantoaxial Rotatory Subluxation. *Spine* 1998; 23:2174-2179.

Return to the BEGINNING of presentation by clicking here or ESC to exit to main screen

Imaging sacral dimples: US or MRI?

- Sacral dimples are common and usually of no significance
- US is the modality of choice in infants < 4-6 months age
  - Sedation risk is higher < 6 months age
- MRI is the modality of choice > 6 months age
- If surgery is planned, it is useful to delay imaging until surgery is imminent

- Caveat: MRI is the study of choice in a child of ANY age with a draining dimple

Return to list of minidiscussions or click anywhere to continue with next topic

Children's Mercy HOSPITALS & CLINICS www.childrensmercy.org

Sacral Dimples: Imaging Low versus High Risk lesions

Low Risk	High Risk
Midline	Off midline
< 5mm	> 5mm
Within 2.5 cm of anus	> 2.5 cm from the anus
No cutaneous abnormalities	Cutaneous abnormalities (i.e. hemangiomas, cutis aplasia, hairy patches, skin tags)

Return to list of minidiscussions or click anywhere to continue with next topic

Children's Mercy HOSPITALS & CLINICS www.childrensmercy.org

Sacral Dimples with cutaneous stigmata: High risk

Hemangioma

Myelomeningocele with skin covering

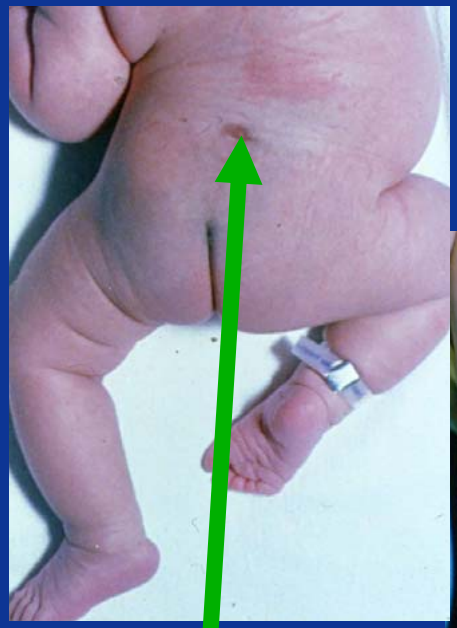

Sacral dimple above gluteal crease

Hairy patch

Return to list of minidiscussions or click anywhere to continue with next topic

Children's Mercy HOSPITALS & CLINICS www.childrensmercy.org

2 children with dimples above the gluteal crease

MR—Child greater than 6 months of age

Dimple that extends to the dural but does violate it

US—Child less than 6 months of age

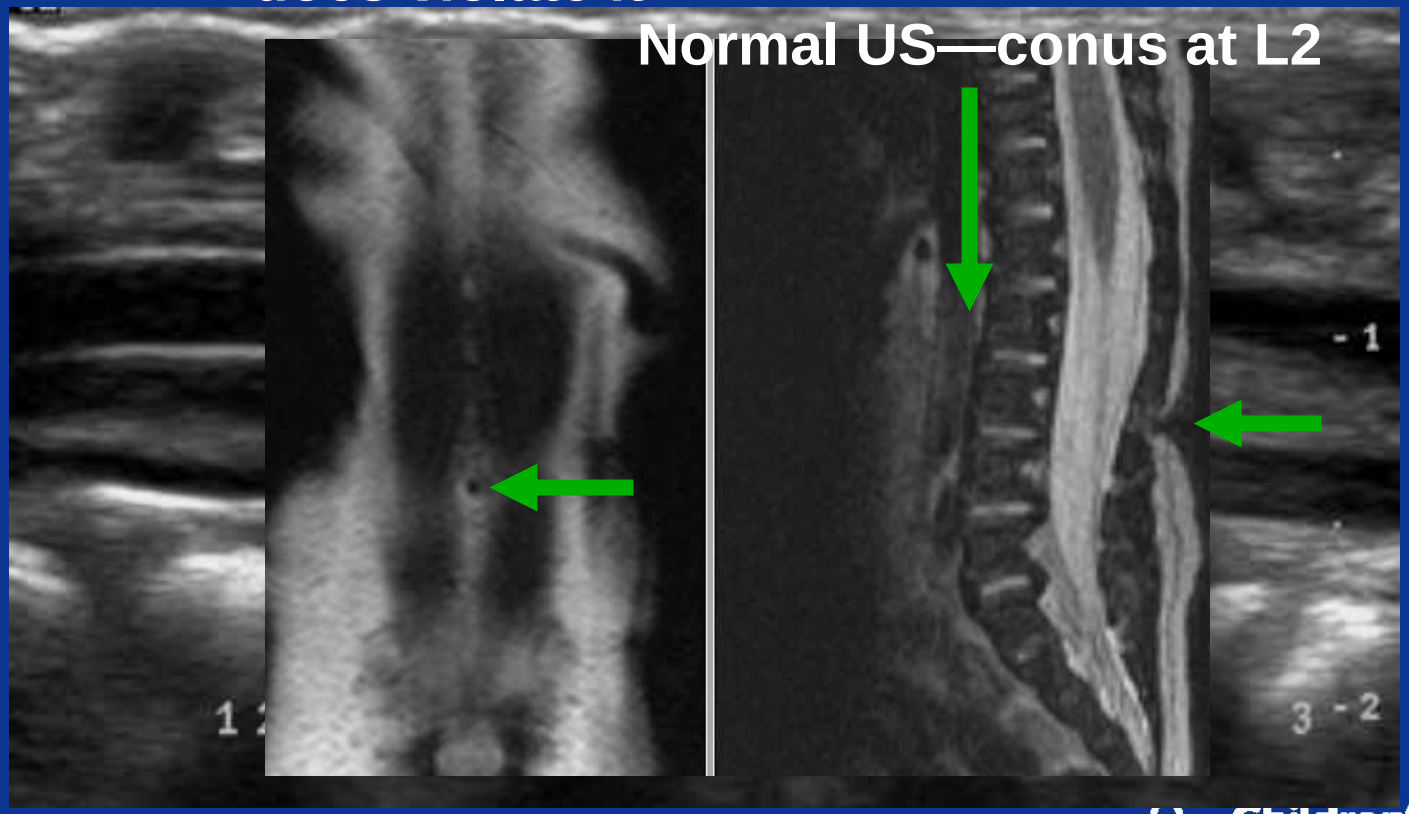

Return to list of minidiscussions or click anywhere to continue with next topic

Children's Mercy HOSPITALS & CLINICS
www.childrensmercy.org

Craniosynostosis Imaging

Imaging is based on 3 categories:

1. **Low risk-** **Developmentally normal or posterior flattening only**
   - **Plain films (4 view skull)**
2. **Intermediate risk -** **Healthy children with head deformity**
   - **CT head**
3. **High risk -** **Obviously misshapen head**
   - **3D CT needed for surgical planning**

Return to list of minidiscussions or click anywhere to continue with next topic

Children's Mercy HOSPITALS & CLINICS www.childrensmercy.org

Craniosynostosis: Low vs. intermediate vs. high risk imaging

Risk Category	Imaging modality recommended
Low risk—developmentally normal and posterior flattening only	4 view skull (plain films)
Intermediate risk—healthy children with head deformity	CT Head
High risk—developmentally abnormal children and/or children with obvious head deformity almost certainly needing surgery	3D Head CT

Return to list of minidiscussions or click anywhere to continue with next topic

Children's Mercy HOSPITALS & CLINICS www.childrensmercy.org

Craniosynostosis: Low Risk

History: Developmentally normal child with posterior flattening

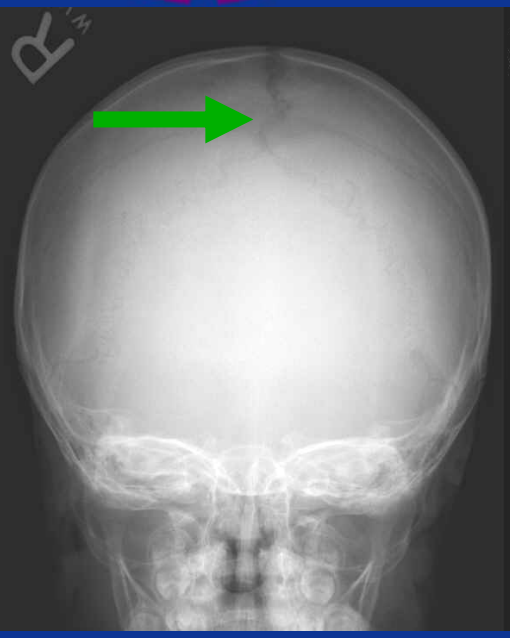

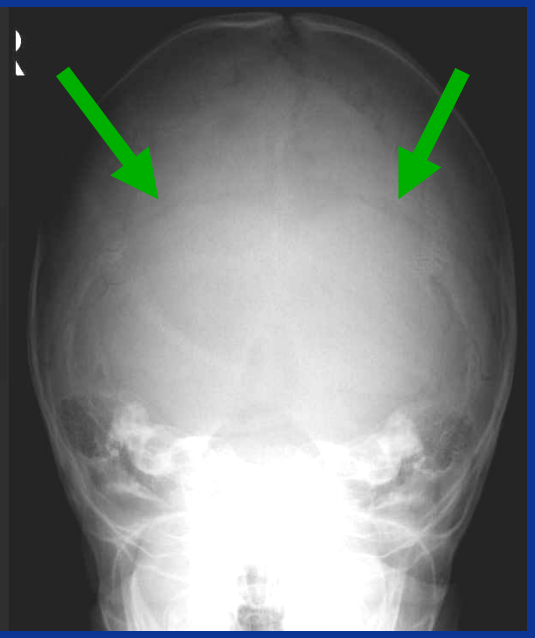

Coronal

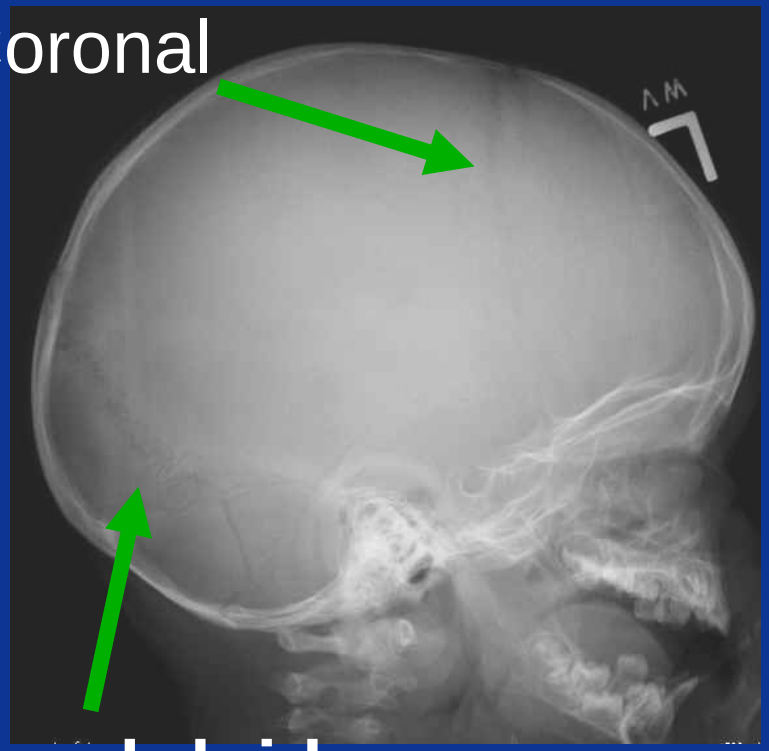

Sagittal **Lambdoid** **Lambdoid**

Diagnosis: Normal sutures

Return to list of minidiscussions or click anywhere to continue with next topic

Children's Mercy HOSPITALS & CLINICS www.childrensmercy.org

Craniosynostosis: Intermediate Risk

History: Developmentally delayed child with parieto-occipital flattening

Diagnosis: Plagiocephaly (parieto-occipital flattening, but no craniosynostosis

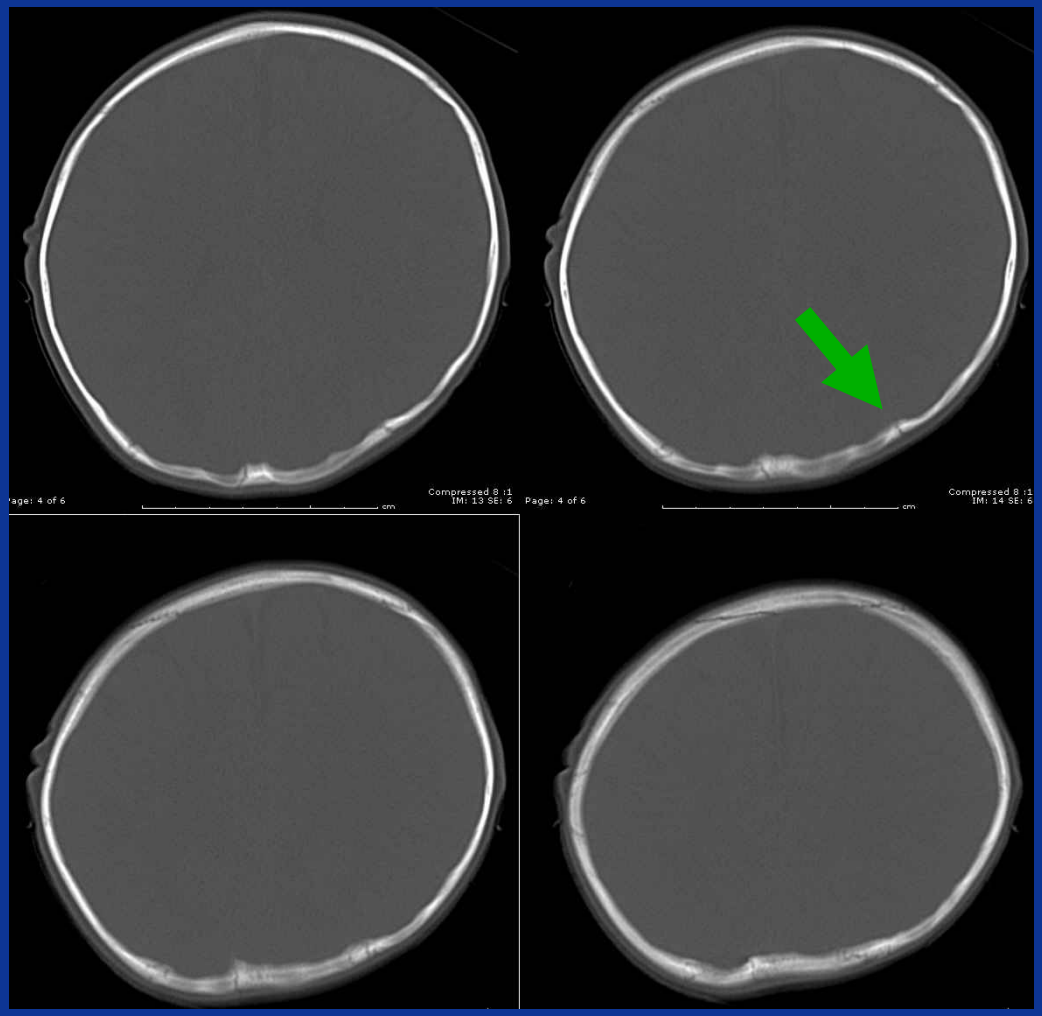

Return to list of minidiscussions or click anywhere to continue with next topic

Children's Mercy HOSPITALS & CLINICS
www.childrensmercy.org

Craniosynostosis: High Risk

History: Child with obvious abnormally shaped head

Diagnosis: Sagittal synostosis

Diagnosis: Lambdoid synostosis

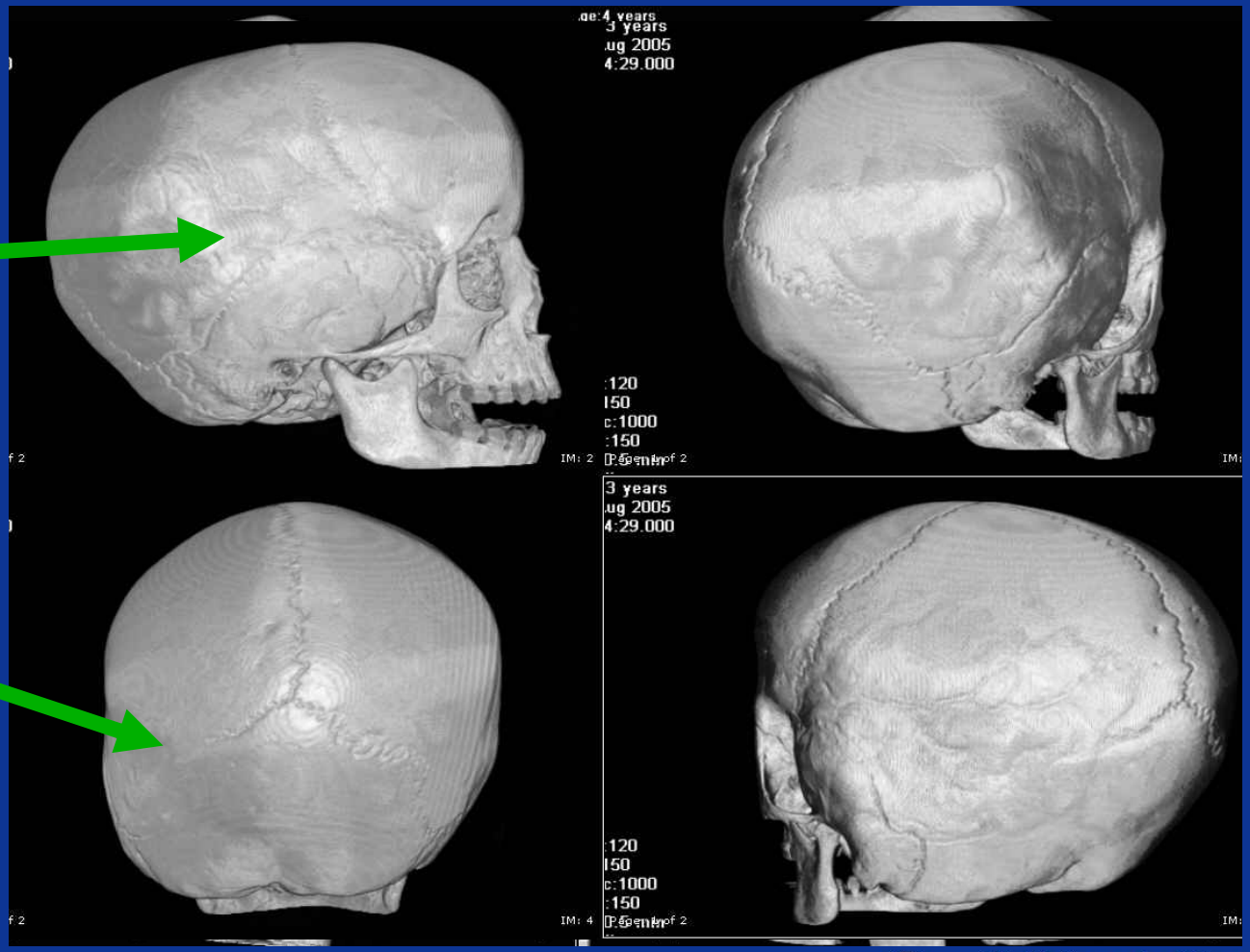

Return to list of minidiscussions or click anywhere to continue with next topic

Children's Mercy HOSPITALS & CLINICS
www.childrensmercy.org

Imaging Torticollis: Based on age and history

- Infant with torticollis:
  - Most often due to fibromatosis coli (hematoma of sternocleidomastoid muscle)
  - More common in forceps delivery
  - Sonography is diagnostic
  - Rx: Physical therapy or surgical release
- Beyond young infants the work up depends on history

Return to list of minidiscussions or click anywhere to continue with next topic

Children's Mercy HOSPITALS & CLINICS www.childrensmercy.org

Torticollis: Beyond infants

- History of isolated torticollis (no trauma)
  - Usually rotatory subluxation (self-limiting, due to muscle spasm)
  - No imaging needed unless persistent after a week or 2 of conservative treatment
  - Isolated, persistent – do CT then consider dynamic scan with head in neutral, right, and left positions
- History of trauma
  - Plain films or CT without contrast
- History of sore throat/signs of infection
  - CT with contrast
- History of torticollis with neurological signs
  - MRI

Return to list of minidiscussions or click anywhere to continue with next topic

Children's Mercy HOSPITALS & CLINICS www.childrensmercy.org

Infantile Torticollis

Hx: 6-week-male with torticollis and forceps delivery

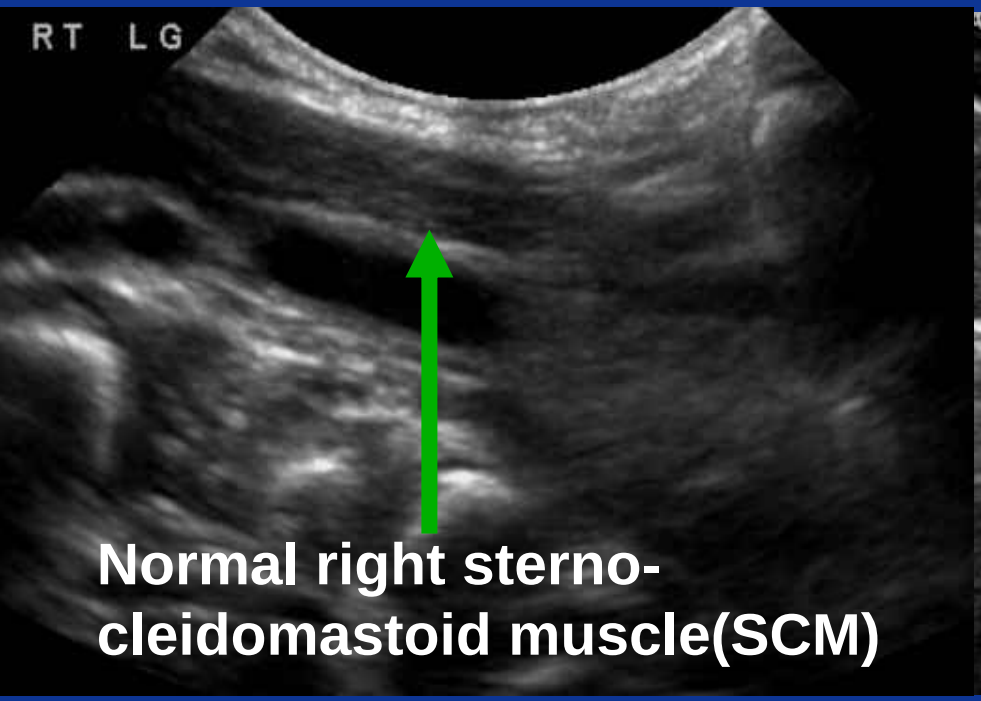

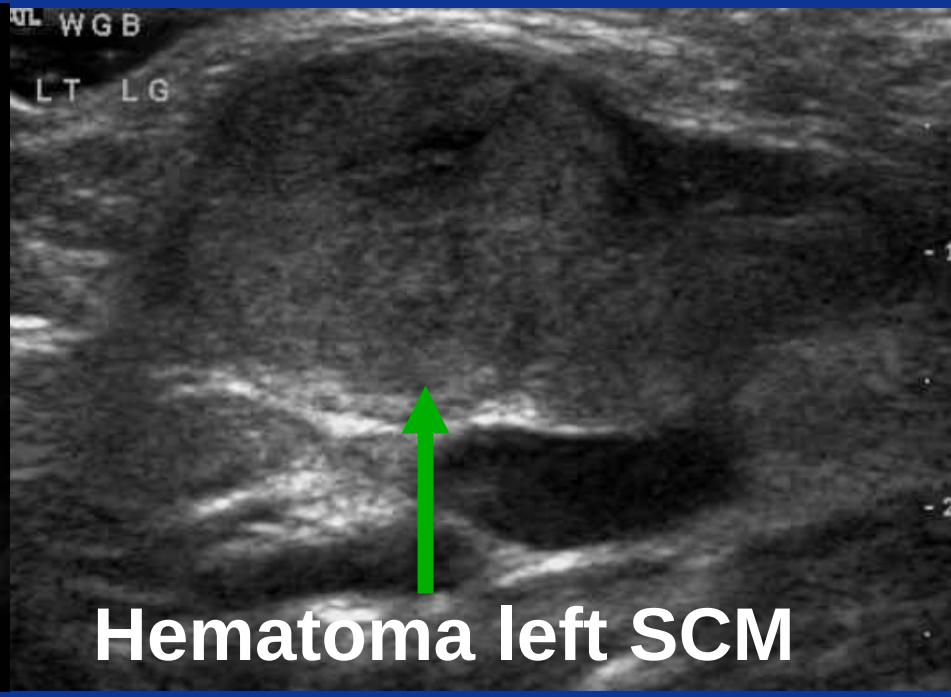

Diagnosis: Fibromatosis coli

Return to list of minidiscussions or click anywhere to continue with next topic

Children's Mercy HOSPITALS & CLINICS
www.childrensmercy.org

Isolated Torticollis in a child

Diagnosis: Rotatory Subluxation

History: 1.9-year-male awakened with neck stuck to left 1.5 weeks ago; No response to conservative treatment

Coronal image demonstrates asymmetry between C1 and C2

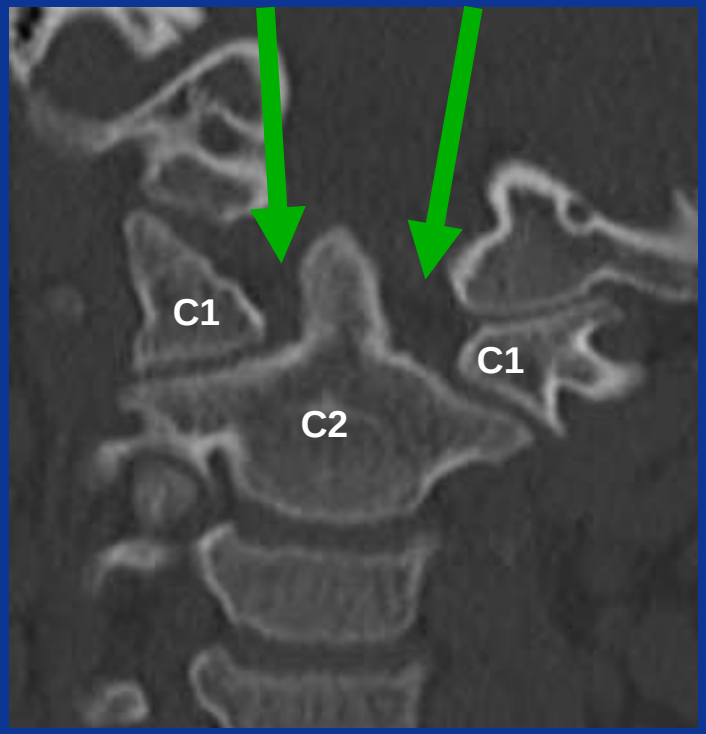

Notice abnormal widening between C1 and dens widens with head turning to the left (toward torticollis)

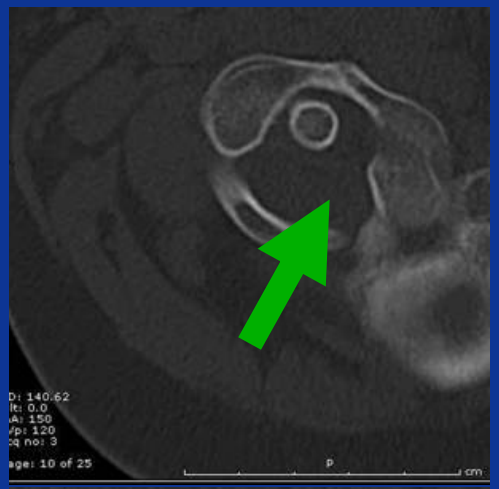

Notice normalization of distance between C1 and dens with head turning to the right (away from torticollis)

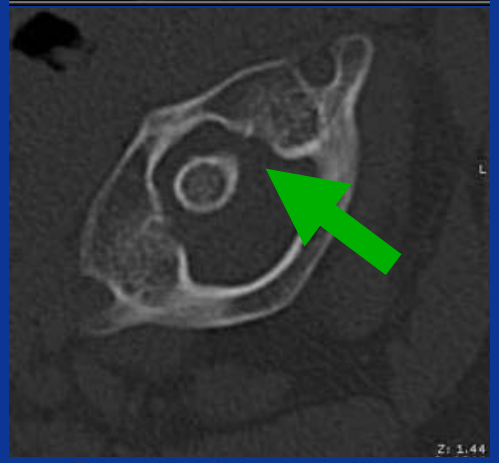

Return to list of minidiscussions or click anywhere to continue with next topic

Children's Mercy HOSPITALS & CLINICS
www.childrensmercy.org

Isolated persistent torticollis

Diagnosis: Rotatory Fixation

History: 15-year-male with neck "stuck to the right" after "neck adjustment"

Normal alignment

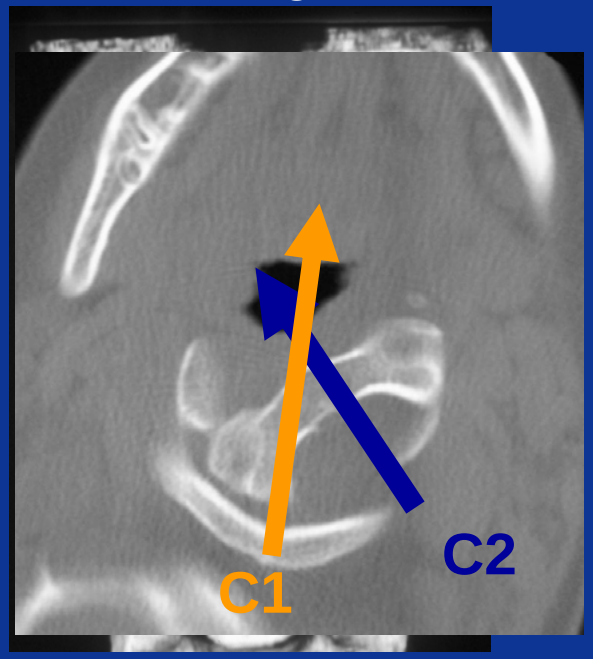

Abnormal alignment with head turning right

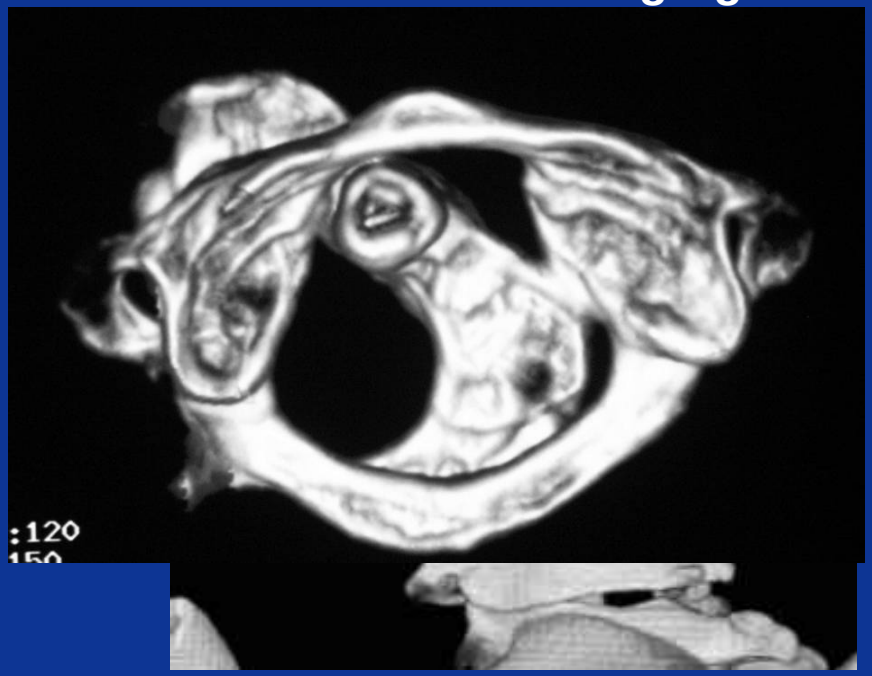

Note C1 is looking a different direction than C2-C7

Return to list of minidiscussions or click anywhere to continue with next topic

Children's Mercy HOSPITALS & CLINICS
www.childrensmercy.org

Torticollis with fever

History: 1-year-female with sore throat and difficulty swallowing

Axial CT neck demonstrates fluid pockets both on the right and at midline

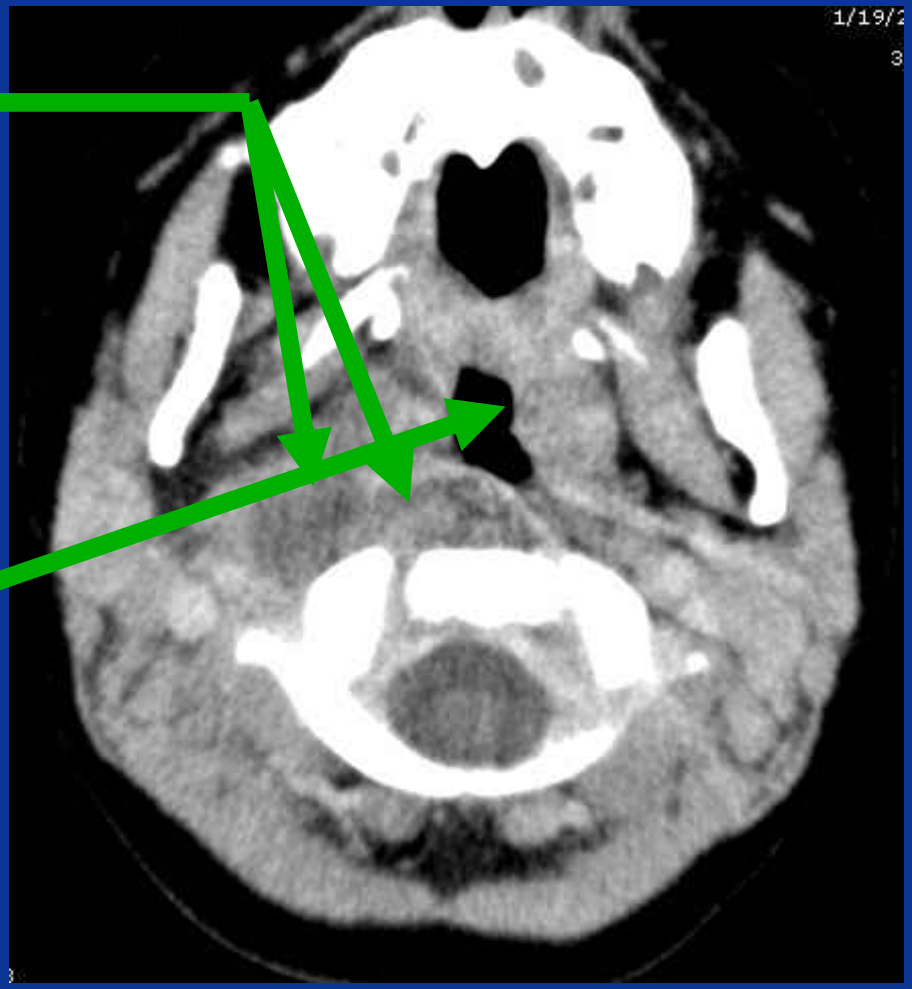

Lateral view of the neck demonstrates prevertebral swelling of soft tissues

Diagnosis: Peritonsillar and retro-pharyngeal infection

Return to list of minidiscussions or click anywhere to continue with next topic

Children's Mercy HOSPITALS & CLINICS www.childrensmercy.org

Torticollis with neurological symptoms

History: 1- yr-female with persistent torticollis & scratching of the left arm

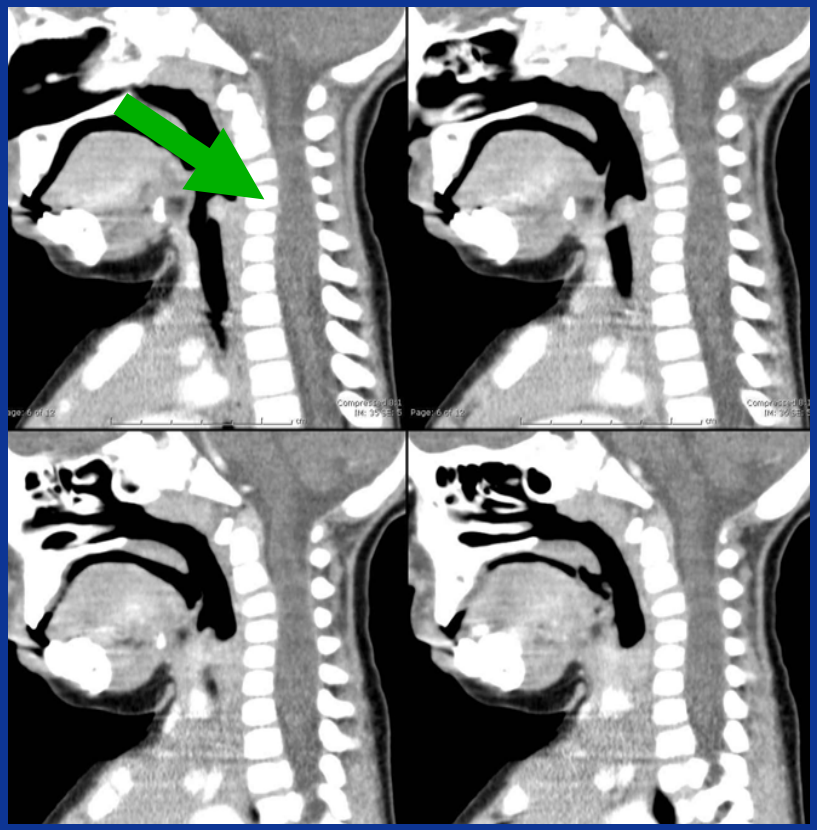

Diagnosis: Spinal cord astrocytoma

Return to list of minidiscussions or click anywhere to continue with next topic

Children's Mercy HOSPITALS & CLINICS
www.childrensmercy.org

Imaging torticollis based on history

Clinical history and age	Initial imaging approach
< 3 months; asymptomatic except for torticollis	Ultrasound
> 3 months; asymptomatic except for torticollis	No imaging; conservative Rx 1-2 weeks; Persistent symptoms –CT without contrast
Any age with history of trauma	CT without contrast
Any age with symptoms of infection	CT with IV contrast
Any age with neurological symptoms	MRI

Return to list of minidiscussions or click anywhere to continue with next topic

Children's Mercy HOSPITALS & CLINICS www.childrensmercy.org

Imaging macrocephaly

Definition: Head greater than 95%

- If the head circumference levels out—no imaging
- If the head growth rate continues to increase or developmental abnormality, do imaging

Imaging approach:

- **US** is used if the child is **less than 6 months** or if they still have an open fontanelle
- **CT** is used if the child is **greater than 6 months** and no fontanelle
- **MRI** if associated neurological symptoms

Return to list of minidiscussions or click anywhere to continue with next topic

Children's Mercy HOSPITALS & CLINICS www.childrensmercy.org

Imaging macrocephaly

Clinical presentation and age	Imaging approach
•Developmentally normal infant/child with open fontanelle	Head ultrasound
•Developmentally normal infant/child with closed fontanelle	CT or MRI
•Developmentally abnormal infant/child with open or closed fontanelle	MRI

Return to list of minidiscussions or click anywhere to continue with next topic

Children's Mercy HOSPITALS & CLINICS www.childrensmercy.org

Macrocephaly: developmentally normal child with open fontanelle

History: Normal subarachnoid space contains vessels

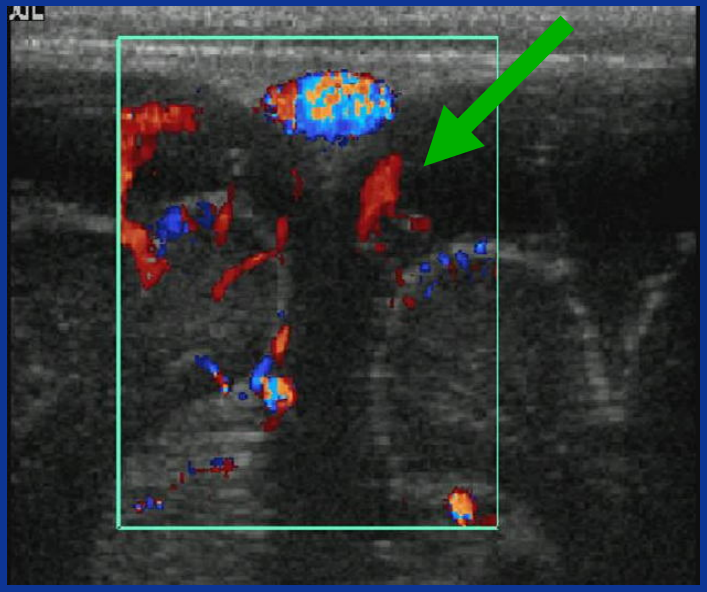

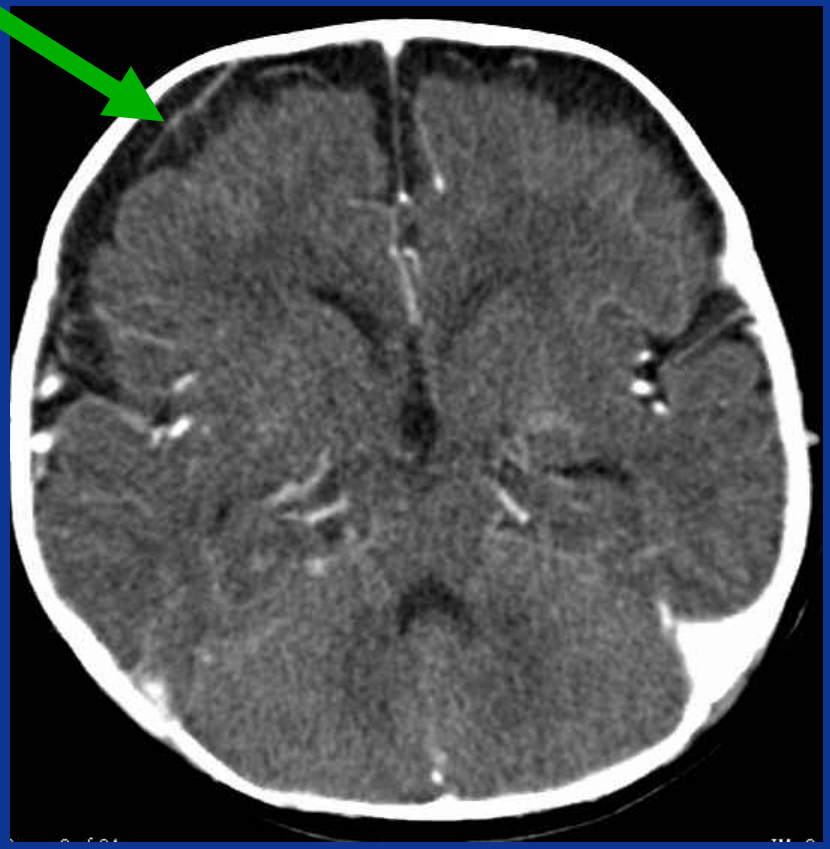

Diagnosis: Benign enlarged subarachnoid spaces

Return to list of minidiscussions or click anywhere to continue with next topic

Children's Mercy HOSPITALS & CLINICS www.childrensmercy.org

Benign enlarged subarachnoid spaces (BESS)

- Usually presents between 3 months and 3 years of age (esp. 6-18mo)
- Most common cause of macrocephaly in a developmentally normal child
- Parents often have big head
- Resolves spontaneously

Return to list of minidiscussions or click anywhere to continue with next topic

Children's Mercy HOSPITALS & CLINICS www.childrensmercy.org

Macrocephaly in a neurologically abnormal child

- **4-month-male with macrocephaly and lethargy**

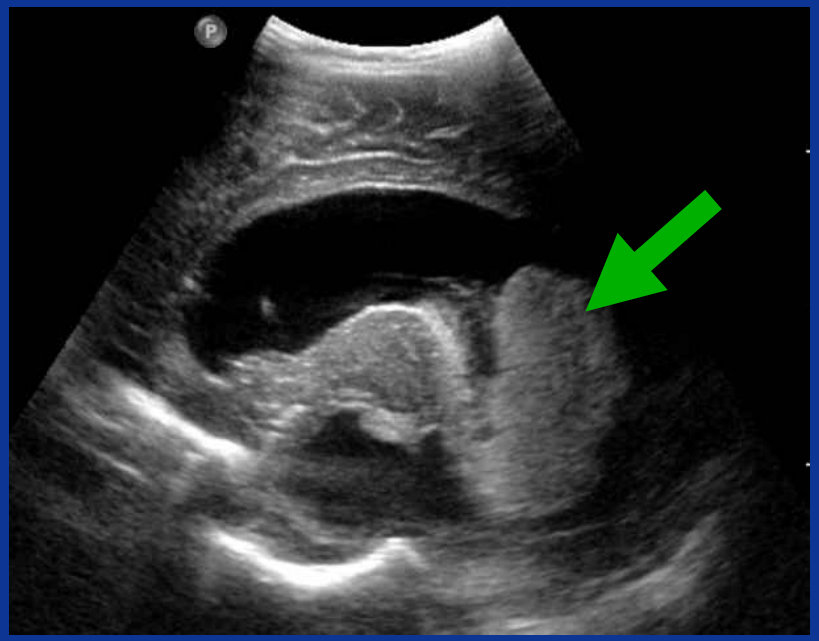

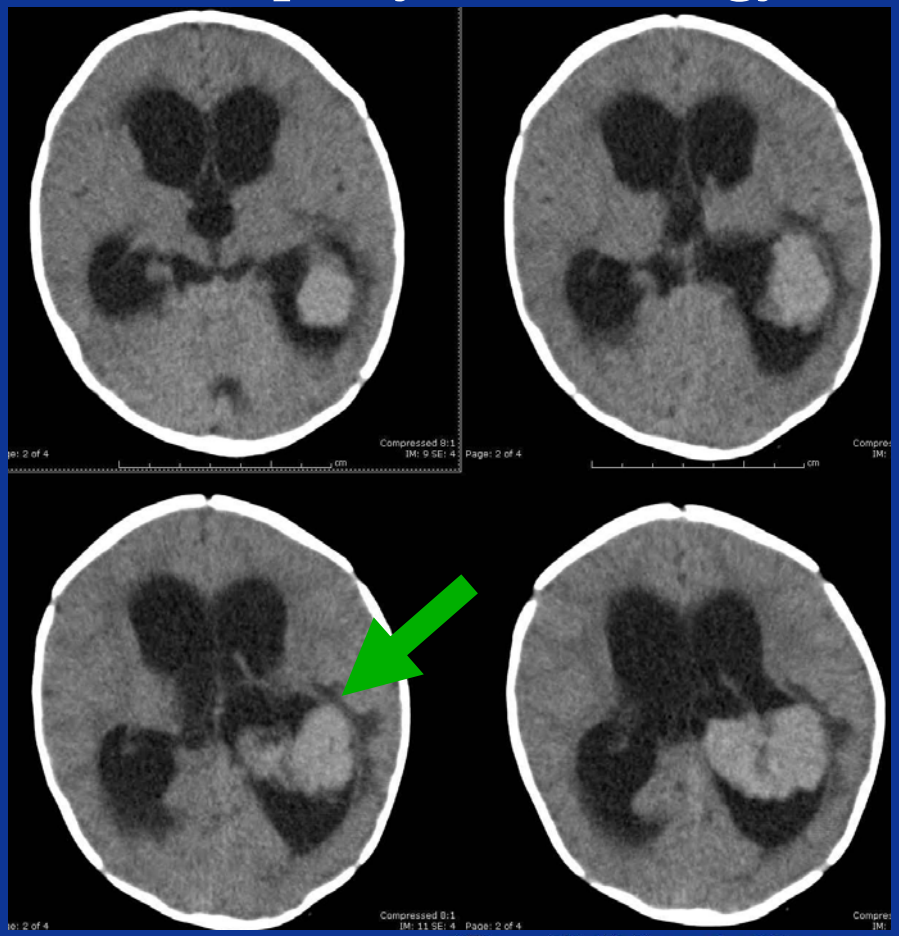

Diagnosis: Choroid plexus papilloma

Return to list of minidiscussions or click anywhere to continue with next topic

Children's Mercy HOSPITALS & CLINICS
www.childrensmercy.org

Vomiting infant: Imaging

- **3 categories:**
- **Bilious vomiting – EMERGENCY**
  - Confirm with NG tube & get UGI
- **Nonbilious vomiting since birth**
  - Not an emergency, and often gastroesophageal reflux
  - Do not need UGI
  - Rx: Anti-reflux meds or surgical consult
- **Projectile vomiting first occurring after several weeks of life**
  - Ultrasound for Pyloric stenosis

Return to list of minidiscussions or click anywhere to continue with next topic

Children's Mercy HOSPITALS & CLINICS www.childrensmercy.org

Vomiting Infant: Bilious

Clinical Presentation	Initial Approach
Bilious Vomiting — Emergency, refer to pediatric facility	NG tube and abdomen radiographs: •If radiographs suggest proximal obstruction (few or no dilated bowel loops) request UGI as malrotation with midgut volvulus is most likely •If radiographs suggest distal obstruction (many dilated bowel loops) request contrast enema first •May need to do both UGI and enema •No need for small bowel follow through

Return to list of minidiscussions or click anywhere to continue with next topic

Children's Mercy HOSPITALS & CLINICS
www.childrensmercy.org

Vomiting Infant: Non-bilious

Non-bilious vomiting •With normal weight gain (often since birth)	•No imaging; GERD most likely •Treat conservatively with anti-reflux meds
Non-bilious vomiting •With airway symptoms (cough, stridor)	•Request UGI •Vascular ring is most likely •No need for small bowel follow through
Non-bilious vomiting •4 to 8 week old	•Pyloric ultrasound •Pyloric stenosis most likely •No need for UGI or small bowel follow through

Return to list of minidiscussions or click anywhere to continue with next topic

Children's Mercy HOSPITALS & CLINICS
www.childrensmercy.org

Vomiting Infant: Bilious

History: 6-day-male with bilious vomiting

Diagnosis: Malrotation with midgut volvulus

UGI reveals obstruction of contrast at the 2nd portion of the duodenum. The contrast column corkscrews down into a beak.

Abdomen

Return to list of minidiscussions or click anywhere to continue with next topic

Children's Mercy HOSPITALS & CLINICS
www.childrensmercy.org

Vomiting Infant: Non-bilious

History: 4-week-male with non-bilious vomiting

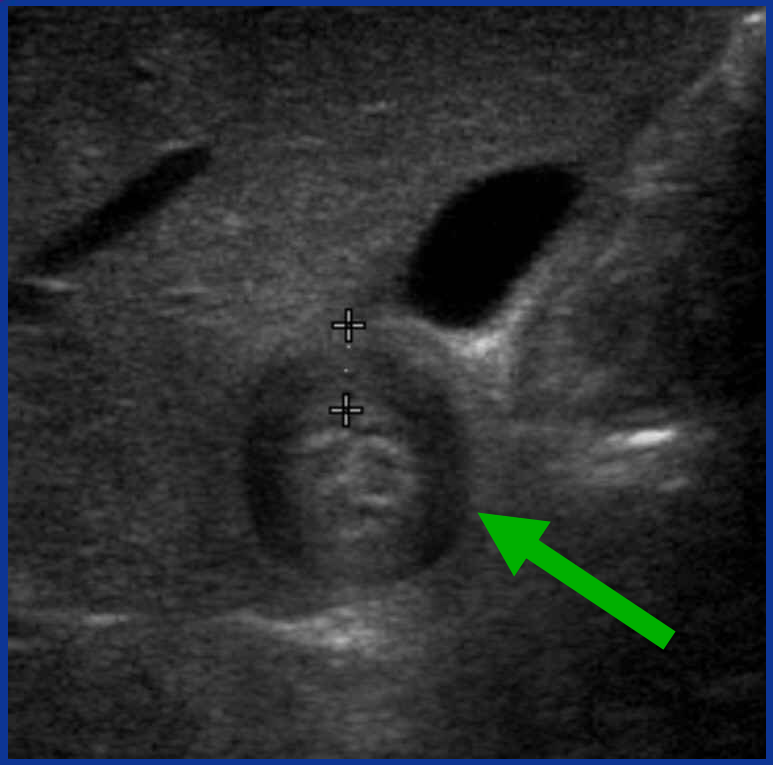

Diagnosis: Pyloric stenosis

- **US shows a thickened (>3mm), elongated pyloric channel(>15mm)**

Return to list of minidiscussions or click anywhere to continue with next topic

Children's Mercy HOSPITALS & CLINICS
www.childrensmercy.org

Imaging the hip: Infants

- **If you suspect hip dysplasia:**
  - **Child age < 4-6 months—ultrasound**
  - **Child age > 4-6 months—plain radiograph**

Return to list of minidiscussions or click anywhere to continue with next topic

Children's Mercy HOSPITALS & CLINICS www.childrensmercy.org

Imaging the hip: Beyond infants

Clinical Presentation	Imaging Study based on degree of suspicion for septic hip
No signs of infection (fever, WBC, ESR) with limp	•Low suspicion-likely toxic synovitis •No imaging needed •If persistent consider plain radiographs for AVN
Signs of infection with mild hip pain or limp	•Intermediate suspicion - MR to evaluate for possible osteomyelitis
Signs of infection with severe pain, decreased ROM, and severe limp or refusal to walk	•High suspicion for septic hip — emergent hip joint tap indicated with or without ultrasound depending on surgeon preference

Return to list of minidiscussions or click anywhere to continue with next topic

Children's Mercy HOSPITALS & CLINICS www.childrensmercy.org

Infant hip < 6 month age

- History: Newborn infant with breech delivery
- Ultrasound shows dislocation of both femoral heads

Femoral heads are not yet ossified and cannot be seen on hip radiographs

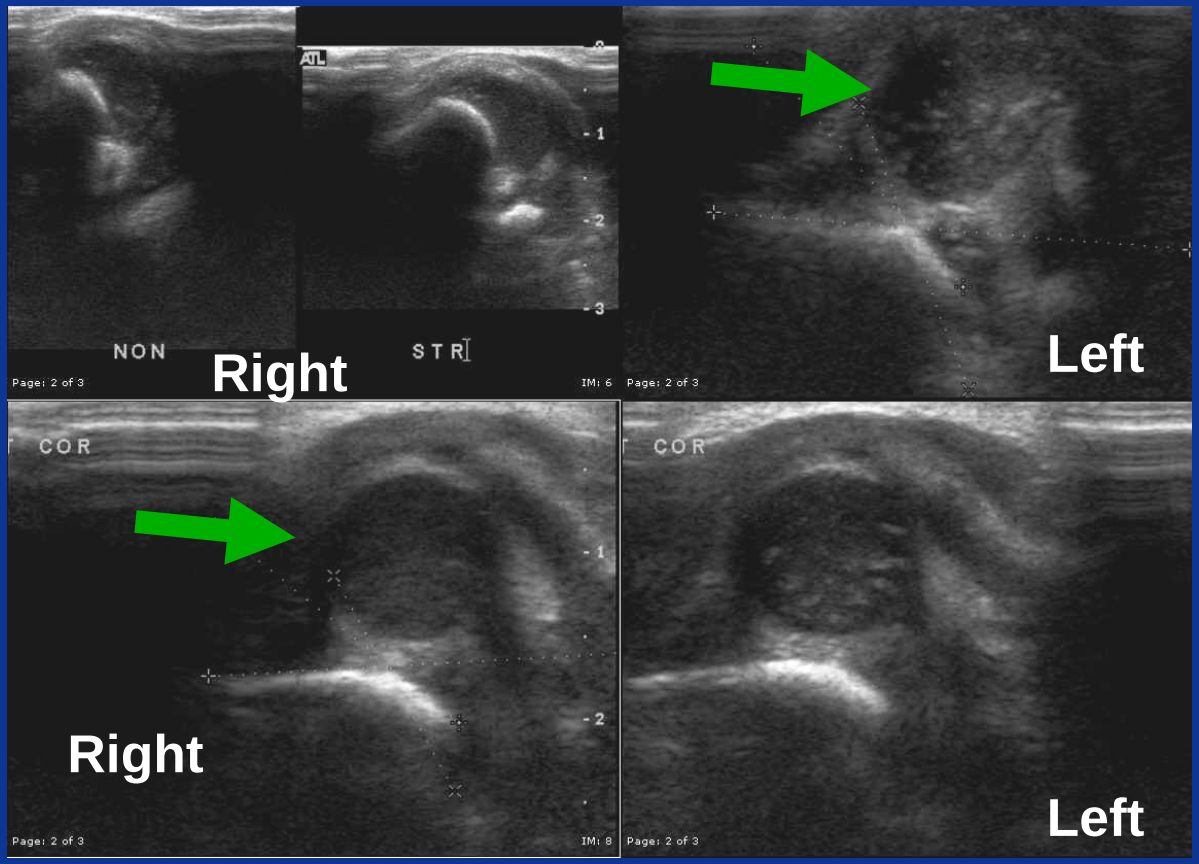

Diagnosis: Hip dysplasia

Return to list of minidiscussions or click anywhere to continue with next topic

Children's Mercy HOSPITALS & CLINICS
www.childrensmercy.org

Child: Intermediate suspicion for septic hip

- 4-year-male with fever, moderate hip pain & limp
- MRI: Enhancing femoral neck/head with associated small effusion

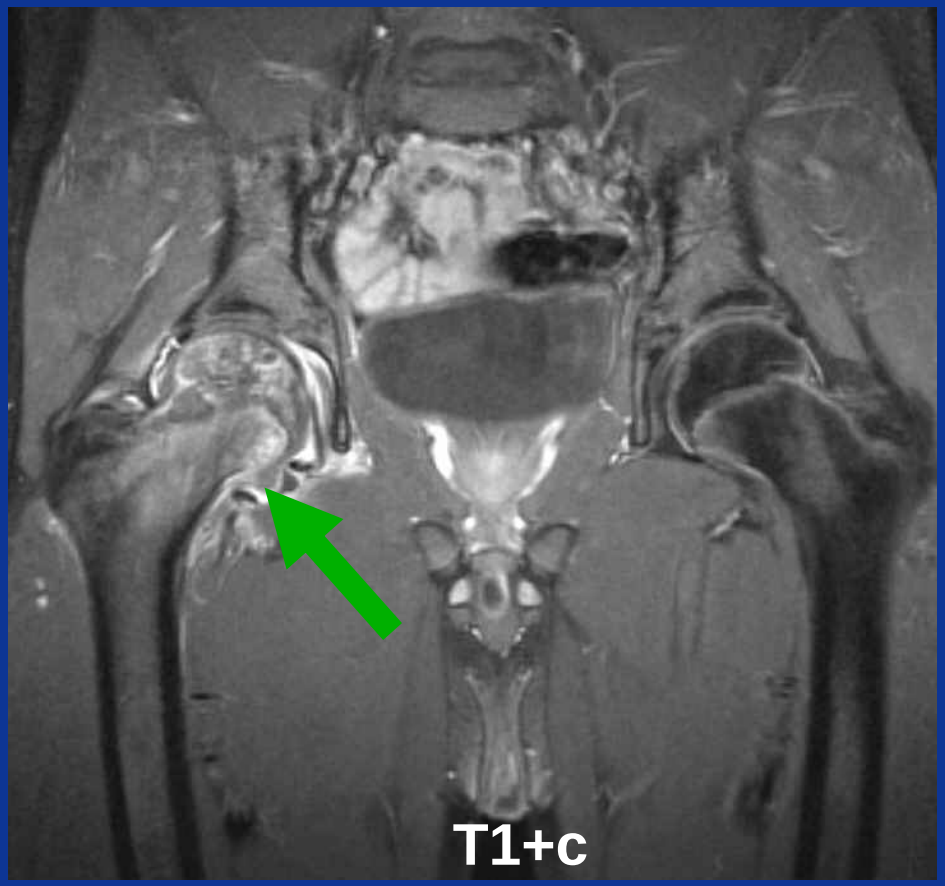

Diagnosis: Osteomyelitis

Return to list of minidiscussions or click anywhere to continue with next topic

Children's Mercy HOSPITALS & CLINICS
www.childrensmercy.org

Child: High suspicion for septic hip

- 3-year-male with fever, severe hip pain and refusal to walk

Diagnosis: Septic hip

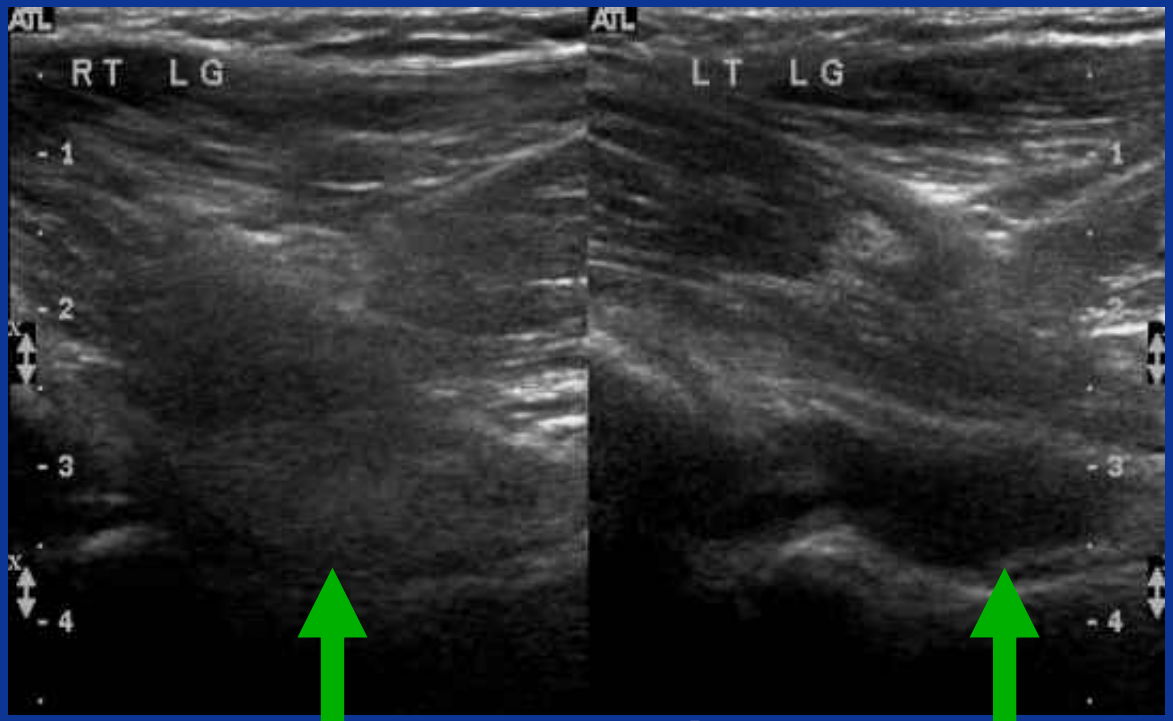

Normal- no fluid

Abnormal- joint effusion

Return to list of minidiscussions or return to start of presentation by clicking here

Children's Mercy HOSPITALS & CLINICS www.childrensmercy.org